

# Direct Inoculation Osteomyelitis Due to *Eikenella corrodens* Following Oral Radiation Therapy

MARY HALE NELSON, HASSAN AZIZ

A 54-year-old male presented to his local otolaryngology clinic following surgical removal of a squamous cell carcinoma of his left tonsil and subsequent chemotherapy and radiation. Large amount of swelling was noticed underneath his chin. Purulent material was drained and cultured revealing *Eikenella corrodens*. The patient was placed on a broad-spectrum intravenous antibiotic therapy and his condition began to improve dramatically.

**OBJECTIVES:** Define the term osteomyelitis and describe the pathogenesis of this condition; identify the common bacterial causes of osteomyelitis; explain the etiologic nature of the organism, *Eikenella corrodens*, and its uniqueness to this case.

**ABBREVIATIONS:** AIDS = acquired immunodeficiency syndrome; CBC = complete blood cell count; CNA = colistin nalidixic acid; CRP = C-reactive protein; CT = computed tomography; ESR = erythrocyte sedimentation rate; HACEK = group of gram-negative bacilli; IV = intravenous; MRI = magnetic resonance imaging; PEG = percutaneous endoscopic gastrostomy; PICC = peripherally inserted central catheter; RBC = red blood cell; WBC = white blood cell.

**INDEX TERMS:** bone tissue infection; *Eikenella corrodens*; osteomyelitis.

Clin Lab Sci 2007;20(1):24

*Mary Hale Nelson MT (ASCP) is Medical Technologist, Candler Hospital, Savannah GA.*

*The peer-reviewed Clinical Practice Section seeks to publish case studies, reports, and articles that are immediately useful, are of a practical nature, or contain information that could lead to improvement in the quality of the clinical laboratory's contribution to patient care, including brief reviews of books, computer programs, audiovisual materials, or other materials of interest to readers. Direct all inquiries to Bernadette Rodak MS CLS(NCA), Clin Lab Sci Clinical Practice Editor, Clinical Laboratory Science Program, Indiana University, Clarian Pathology Laboratory, 350 West 11th Street, 6002F, Indianapolis IN 46202. brodak@iupui.edu*

*Hassan Aziz PhD CLS (NCA) is Department Head of Medical Technology, Armstrong Atlantic State University, Savannah GA.*

*Address for correspondence: Hassan Aziz PhD CLS (NCA), Department Head of Medical Technology, Armstrong Atlantic State University, 11935 Abercorn Street, Savannah GA 31419. (912) 921-7448, (912) 921-5585 (fax). azizhass@mail.armstrong.edu.*

This paper has not been presented at a meeting nor has it been accepted for presentation at a future meeting.

## CASE HISTORY

A 54-year-old African American male presented to his local otolaryngology clinic for follow-up after undergoing surgical removal of a squamous cell carcinoma of his left tonsil and subsequent chemotherapy and radiation. At his follow-up, the patient complained of a large amount of swelling underneath his chin that had been present for one week. He had difficulty swallowing and was continuing to depend on a percutaneous endoscopic gastrostomy (PEG) tube for feeds.

The anterior border of his chin and the floor of his mouth were tender upon palpation. An exam of his oral cavity revealed an exposed mandible, which had been exposed previously during his radiation treatments. The exposed area was purulent and 20 ml of pus was removed, alleviating most of the swelling. An incision was made to complete the drainage process paying special attention to minimize contamination with normal oral flora. Cultures were ordered on the retrieved purulent material. An infectious disease consult was obtained which recommended that the patient be treated with six weeks of intravenous (IV) imipenem.

The patient was admitted to the hospital for a course of three days. Upon admittance, a series of complete blood cell counts (CBC) and basic metabolic panels were ordered (Table 1), his peripherally inserted central catheter (PICC) line for antibiotic therapy was placed, and a computed tomography (CT) scan of his neck area was obtained. He was discharged under the care of home health nursing. He required daily IV

imipenem administration and packing changes for his drainage incision. His discharge medications included Peridex mouthwash, Miles Magic Mouthwash, Lortab elixir via PEG tube as needed for pain, one gram of IV imipenem every 24 hours for six weeks, and eight cans per day of Jevity tube feed. The patient was instructed to follow-up with his oncologist in six weeks and his infectious disease specialist in three to four weeks. Several days after the patient was released from the hospital, a final microbiology report revealed growth of *Eikenella corrodens* and microaerophilic *Streptococcus* in the purulent material.

### OVERVIEW OF OSTEOMYELITIS

Osteomyelitis is an infection of bone tissue caused by pyogenic bacteria. There are two basic routes of infection: hematogenous (via a bacteremia) and direct inoculation, as in this case. Direct inoculation osteomyelitis occurs when bacteria are introduced to bone by a direct trauma, such as open wounds induced by radiation therapy. Radiation can cause a condition known as osteoradionecrosis, in which bony tissues are destroyed, making them extremely susceptible to infection. Osteoradionecrosis of the mandible, specifically, is a very common side effect of radiation therapy of the head and neck.<sup>1</sup> This condition, combined with open sores caused by radiation and chemotherapy, creates the perfect opportunity for the onset of osteomyelitis. Once the bone is exposed to a pathogen, the infection may spread from the periosteum to the marrow and spongy bone. The etiologic agent depends solely on the patient's age and mode of infection; however, the most common bacteria isolated from acute and direct osteomyelitis in adults include *Staphylococcus aureus*, and *Streptococcus*, *Enterobacter*, and *Pseudomonas* species.<sup>2</sup> Thus, the finding of microaerophilic *Streptococcus* in this case is unremarkable in contrast to the rare isolation of *Eikenella corrodens*.

### EIKENELLA CORRODENS AS A PATHOGEN

The bacterium *Eikenella corrodens* is a gram-negative facultative bacillus that causes opportunistic infections in humans. It is found among the oral, gastrointestinal, and genitourinary normal flora and its virulence factors are unknown. It belongs to a group of organisms, denoted as the acronym HACEK, that has the ability to inflict subacute bacterial endocarditis. HACEK refers to gram-negative bacilli: *Haemophilus* species (*H parainfluenzae*, *H aphrophilus*, and *H paraphrophilus*), *Actinobacillus actinomycetemcomitans*, *Cardiobacterium hominis*, *Eikenella corrodens*, and *Kingella* species. *Eikenella corrodens*, however, is best recognized as a pathogen in human bite wounds, oral infections, and clenched fist wounds

associated with facial punches. Researchers have reported *Eikenella* sp. as an etiologic agent in osteomyelitis, but this is extremely rare.<sup>3,4</sup> Interestingly, the literature repeatedly mentions a suspected synergy between the pathogenicity of *E. corrodens* and *Streptococci*, as they were often isolated together in polymicrobial infections.<sup>5</sup>

### DIAGNOSIS OF OSTEOMYELITIS

Diagnosis of osteomyelitis requires two of the following four criteria: localized edema and tenderness, positive microbiology culture, aspiration of purulent material from the infected bone, and evidence of osteomyelitis in imaging studies.<sup>2</sup> Direct inoculation osteomyelitis is usually localized with obvious signs and symptoms. These may include fever, edema, warmth, fluctuance, and tenderness upon palpation of the infected area; and a reduced ability to utilize the infected area, i.e., the inability to swallow in this case. Imaging studies, such as radiography, magnetic resonance imaging (MRI), bone scanning, CT scanning, and ultrasonography may be performed to evaluate bone damage.

The laboratory also plays a crucial role in diagnosis. The CBC results may or may not reflect an elevated WBC count; however, a left shift in the WBC differential is common, as is an increase in the percentage of segmented neutrophils. An increase in neutrophils is commonly indicative of bacterial infections but was not present in this particular case. This patient exhibited a low WBC count on day one, and normal counts on days two and three. These relatively low values are most likely related to the patient's recent dosages of chemotherapy. The decreased number of RBCs and platelets supports this correlation. Monocytosis was seen in this patient, an indication of the persistent severity of his infection. The C-reactive protein (CRP) level and the erythrocyte sedimentation rate (ESR) are usually elevated in osteomyelitis. These tests are a very general indication of any inflammation present and were apparently not ordered for this patient during his hospital admission (Table 1).

In order to identify the etiologic agent of osteomyelitis, cultures must be performed. Unfortunately, pathogens are not isolated in 25% of cases.<sup>2</sup> In this case, the laboratory was able to identify the presence of microaerophilic *Streptococcus* species and *E. corrodens*. The *Streptococcus* organism was identified by growth characteristics and by a biochemical "ruling-out" process. It grew poorly in ambient air on blood, chocolate, and colistin-nalidixic acid (CNA) agars. It grew slightly better with supplemental CO<sub>2</sub>. The colonies were alpha hemolytic and of pinpoint size. Susceptibility testing via the Kirby

Bauer disk diffusion method revealed that the organism was susceptible to penicillin, cefotaxime, and vancomycin. Due to its characteristic slow growth, *E. corrodens* cannot easily be identified by automated methods. Figure 1 illustrates the typical biochemical reactions utilized to confirm the isolation of this bacterium. The gram negative bacilli organism was presumptively identified based on the following: slow growth on blood agar, no growth on MacConkey agar, a bleach-like odor, and characteristic “pitting” colonies. *E. corrodens* was oxidase positive but did not utilize any carbohydrates. It was catalase, urease, and indole negative. It did not hydrolyse arginine though ornithine was decarboxylated. No susceptibility testing was performed on the *Eikenella* isolate per laboratory protocol; however, it was found to produce beta-lactamase. The presence of this enzyme meant that the isolate was resistant to antibiotics, such as penicillin, that contain a beta-lactam ring.<sup>6</sup>

**TREATMENT OF *EIKENELLA*-BORNE OSTEO-MYELITIS**

The most desirable treatment for osteomyelitis is prevention via proper wound care and prophylactic antibiotics, but this is not always possible. Empiric antibiotic therapy, or therapy that is begun before the etiologic agent of an infection is identified, must sometimes be utilized. The decision to give this patient IV imipenem was empiric because the drug was given before *E. corrodens* and microaerophilic *Streptococcus* were isolated. Empiric therapy may be changed once the pathogen is recognized. Regardless of the choice of antibiotic, four weeks to six weeks of intravenous therapy are required for osteomyelitis. Once that time period has lapsed, IV therapy may be continued or replaced with oral therapy. *Eikenella* sp. are resistant to antibiotics, such as clindamycin and metronidazole, which are typically effective against oral flora. This makes empiric therapy difficult. Disk

Downloaded from <http://hwmainit.clsiournal.ascls.org/> on April 17 2024

**Table 1.** Select patient laboratory results

Test	Day 1	Day 2	Day 3	Follow-up appointment	Reference range
WBC	3.75	5.13	6.47	NP	4.80-10.80 x 10 <sup>3</sup> /mm <sup>3</sup>
Neutrophil	67.2	69.4	71.6	NP	50.0%-75.0%
Lymphocyte	14.2	11.6	12.3	NP	20.0%-45.0%
Monocyte	15.6	17.2	15.0	NP	0.0%-10.0%
RBC	3.67	3.90	3.60	NP	4.70-6.10 x 10 <sup>6</sup> /mm <sup>3</sup>
Platelet	146	151	167	NP	140-440 x 10 <sup>3</sup> /mm <sup>3</sup>
Sodium	143	139	138	141	135-145 mmol/L
Potassium	4.1	3.7	3.7	4.0	3.5-5.0 mmol/L
Chloride	103	103	105	106	98-107 mmol/L
CRP	NP	NP	NP	0.32	0.00-0.74 mg/dL

Day 1, 2, and 3 after initial hospitalization

\* NP: not performed

† CRP: C - reactive protein

diffusion susceptibility testing is difficult to perform due to the organism's characteristic slow growth, further complicating the situation. Practical experience has shown that penicillin, ampicillin, tetracycline, chloramphenicol, and some cephalosporins are effective against these bacteria.<sup>7</sup>

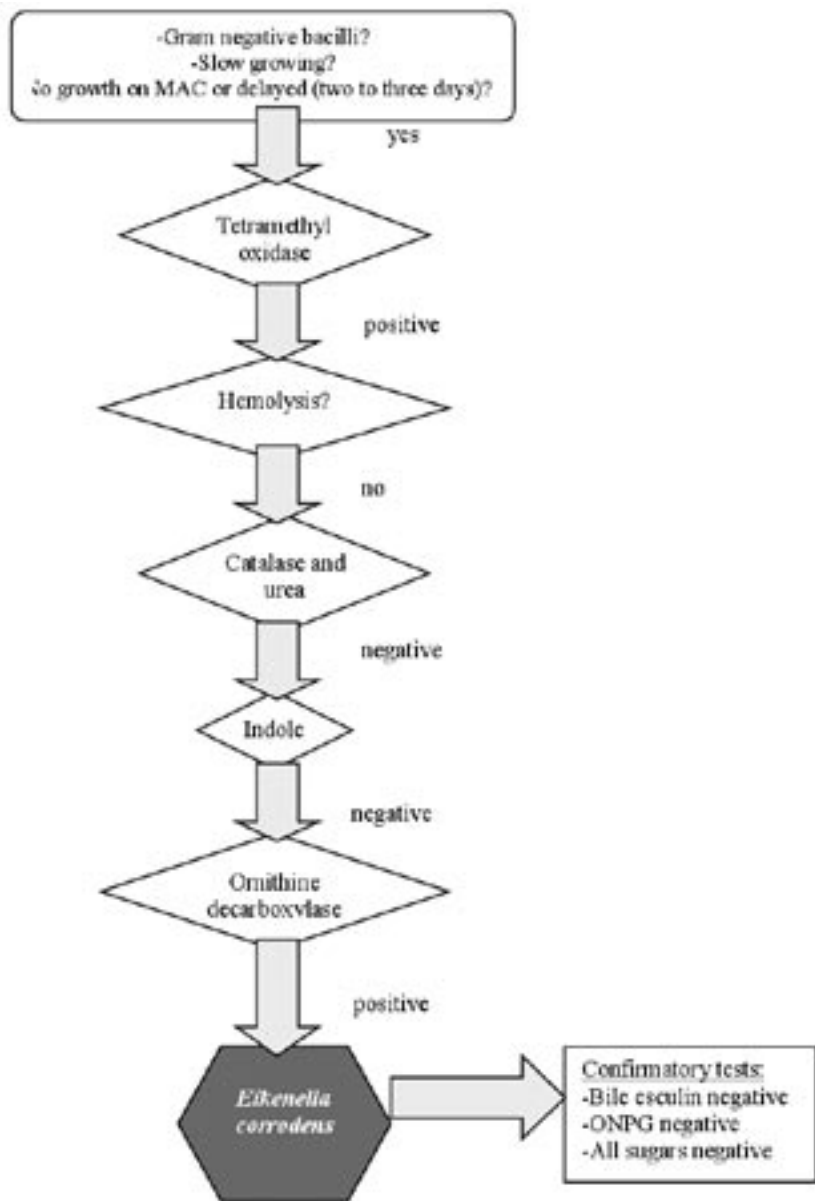
If antibiotic treatment fails to combat an osteomyelitis infection, surgical intervention may be necessary.

**PROGNOSIS OF OSTEOMYELITIS**

The prognosis of direct inoculation osteomyelitis varies. Without proper treatment or if treatment

is unsuccessful, the condition can become chronic and may lead to amputation of the infected bone. Early identification of the problem and administration of the proper antibiotic therapy are crucial. Mortality rates are low, except in circumstances associated with sepsis or an underlying condition, such as AIDS.

**Figure 1.** Identification scheme for *Eikenella corrodens*



**CASE CONCLUSION**

Six weeks after his follow-up appointment at the otolaryngology clinic, the patient was seen by his infectious disease specialist. The physician concluded that the patient had responded well to the IV imipenem therapy and decided that his PICC line should be removed. According to recent laboratory results, his basic metabolic panel was normal and his C-reactive protein was within normal limits (Table 1). Because the patient still had an exposed mandible, oral augmentin therapy was begun. Augmentin, which contains a beta-lactamase inhibitor, was the antibiotic of choice due to the beta-lactamase producing *E. corrodens* isolated from the aspirate culture.

**SUMMARY**

This case study reviews a common disease, direct inoculation osteomyelitis, with an uncommon etiologic agent, *Eikenella corrodens*. Direct inoculation osteomyelitis involves a direct route for infection between the opportunistic pathogen and the affected bone. The direct route in this case was an exposed mandible, creating a perfect situation for infection by an oral flora organism. Treatment of this particular infection could easily have been unsuccessful because *E. corrodens* is not responsive to most antibiotics used to treat other oral flora bacteria. The infectious disease consult recommended a broad-spectrum IV antibiotic, imipenem, to

Downloaded from <http://hwmain.clinical-lab.com> on April 17 2024

## CLINICAL PRACTICE

be administered by skilled home health nursing staff. This empiric decision, in addition to the patient's strict compliance with the physician's orders, including proper use of prescribed mouthwashes and timely follow-up with the necessary specialists, resulted in a very positive prognosis.

### REFERENCES

1. Meiteles L, Josephson GD, Spencer RW, and others. Osteoradionecrosis of the temporal bone. *Ear Nose Throat J* 1998;77:56-7.
2. King RW, Johnson D. (2005, June). Osteomyelitis. Available from <http://www.emedicine.com>. Accessed 2005 Sep 5.
3. Polin K, Shulman ST. *Eikenella corrodens* osteomyelitis. *Pediatrics*. 1982;70:462-3.
4. Dorff GJ, Jackson LL, Rytel MW. Infections with *Eikenella corrodens*. *An Intern Med* 1974;80:305-9.
5. Knudsen TD, Simko EJ. *Eikenella corrodens*: an unexpected pathogen causing a persistent peritonsillar abscess. *Ear Nose Throat J* 1995;74:114-6.
6. Forbes BA, Sahm DF, Weissfeld AS. *Bailey and Scott's Diagnostic Microbiology* (11<sup>th</sup> ed.). St. Louis: Mosby, Inc.; 2002.
7. Paul K, Patel S. *Eikenella corrodens* infections in children and adolescents: case reports and review of the literature. *Clin Infect Dis* 2001;33:54-61

### ASCLS SIGNATURE LINE -CUSTOMIZED APPAREL-

Sport shirts \* Denim shirt \* T-shirts  
\* Sweatshirt/pants \* and more!  
Affordable leisure wear

American Society for  
Clinical Laboratory Science  
301-657-2768 [www.ascls.org](http://www.ascls.org) [joanp@ascls.org](mailto:joanp@ascls.org)



ORDER YOURS AT THE ASCLS  
ONLINE STORE  
[www.ascls.org](http://www.ascls.org),  
click on Education,  
then click on the link to the Store