

Aspergillus terreus Recovered from a Corneal Scraping

SUZANNE CAMPBELL

ABSTRACT

A 52 year old, healthy male presented to his optometrist complaining of redness and irritation in the right eye. A foreign body was removed from the eye. The patient was started on ophthalmic solutions of vigamox and systane. At 48 hours, the patient reported increased redness, limited vision, and yellow discharge from the eye. The patient was referred to an ophthalmologist for further evaluation. Physical assessment revealed a superlative central infiltrate (extreme, centrally located injury that had permeated the cornea), diffuse corneal haze, and edema with a 3- to 4+ conjunctival injection and a 1 millimeter hypopyon (an effusion of pus into the anterior chamber of the eye).¹ Corneal scrapings were collected for aerobic and anaerobic bacterial and fungal cultures. The patient was then prescribed vancomycin, tobramycin, and natamycin ophthalmic eyedrops. On day three, fungal culture results indicated possible fungal forms seen. On day 12, results from the fungal culture of the corneal scraping revealed the causative agent to be *Aspergillus terreus*. Voriconazole eyedrops were added to the treatment regimen and continued for 10 weeks. The physician order for a fungal culture as well as laboratory data providing the final identification of *Aspergillus terreus* and laboratory comments indicating an elevated minimum inhibitory concentration (MIC) (> 2 µg/mL) to amphotericin B is associated with treatment failure positively impacted the patient outcome. After completion of the treatment regimen, a photo-therapeutic keratectomy (PTK) was performed in an attempt to remove the dense corneal scarring caused by the fungal infection.

ABBREVIATIONS: Photo-therapeutic keratectomy – PTK; invasive aspergillosis –IA; deoxyribose nucleic acid –DNA; real time polymerase chain reaction - rt-PCR; amphotericin B – AMB; intravenous – IV; Food and Drug Administration – FDA; minimal inhibitory concentration – MIC.

INDEX TERMS: *Aspergillus terreus*, Aspergillosis, real-

time polymerase chain reaction, triazoles

Clin Lab Sci 2014;27(2):67

Suzanne Campbell, PhD, MLS(ASCP)^{CM}, Seward County Community College/Area Technical School, Liberal, KS

Address for Correspondence: Suzanne Campbell, PhD, MLS(ASCP)^{CM}, MLT Program Coordinator, Seward County Community College/Area Technical School, 520 N. Washington Liberal, KS 67901-620.417.1403 suzanne.campbell@sccc.edu

INTRODUCTION

A 52 year old healthy male presented to his optometrist complaining of redness and irritation in his right eye. Contact lenses were worn to correct his vision. The patient had been scuba diving in south Miami Beach and reported the sensation of a foreign body in the eye. He was started on ophthalmic solutions of vigamox and systane. At 48 hrs, the patient reported increased redness, limited vision, and yellow discharge from the eye. The patient was referred to an ophthalmologist/corneal specialist for evaluation. The patient's corrected vision was hand motion at 12 inches in the right eye. Physical assessment revealed a superlative central infiltrate (extreme, centrally located injury that had permeated the cornea), diffuse corneal haze and edema with a 3- to 4+ conjunctival injection and a 1 millimeter hypopyon (an effusion of pus into the anterior chamber of the eye).¹

Initially, the patient was started on two ophthalmic solutions – vancomycin and tobramycin. After receiving laboratory data that indicated possible fungal forms seen via culture on day three, natamycin was prescribed. Vancomycin, a glycosylated cyclic peptide, is used to treat infections due to Gram positive cocci and was initially administered via ophthalmic solution (25 mg/mL, 2.5%) every hour. The aminoglycoside,

tobramycin (14 mg/mL, 1.4%) was administered every hour as an antimicrobial agent against Gram negative bacteria. Natamycin, an antifungal agent, is used to treat corneal fungal infections and was given every two hours. On day three of treatment, the frequency of the ophthalmic solutions was decreased to every two hours. Voriconazole (10 mg/mL), a triazole with known *Aspergillus terreus* susceptibility, was added to the regimen on day 12 and was administered hourly. Administration of the vancomycin and tobramycin were discontinued after five weeks of treatment. The frequency of the voriconazole dosage was gradually decreased to twice a day administration and was continued for ten weeks.

The ophthalmologist collected corneal scrapings that were submitted for aerobic and anaerobic bacterial and fungal cultures. The aerobic and anaerobic bacterial cultures were negative. The initial report from the fungal culture indicated rare growth of mycelia fungal forms. The specimen was sent to a reference laboratory for identification. The fungus was identified as *Aspergillus terreus* by phenotypic methods. Phenotypic methods are based on colony morphology, microscopic morphology and growth rates

PATHOGENESIS

Nondermatophyte filamentous fungi are commonly found in the environment. *Aspergillus terreus* is 1 of 20 *Aspergillus* species to cause opportunistic infections in humans and is found in soil, decaying matter, household dust, building materials and on plants.² More than 30 species are reported in human and animal infections.³ Previously, the most commonly identified species included *Aspergillus fumigatus* and *Aspergillus flavus*.⁴

Aspergillus terreus is emerging as a cause of fungal infections. This fungus is widespread in warm arable soils, especially in southern and southwestern United States but is less common in the forest than cultivated soils. It is rarely found in acidic forest soils from colder temperate zones.⁴

Infections due to *Aspergillus terreus* are classified as invasive, saprophytic, or allergic. *Aspergillus terreus* has been the etiologic agent in lung disease, allergic bronchopulmonary disease, allergic sinusitis, cutaneous infections, invasive bronchopulmonary disease,

intradural spinal biopsy, nosocomial aspergillosis, peritonitis, and invasive aspergillosis.²⁻³ Invasive bronchopulmonary aspergillosis is life threatening in an immunocompromised patient. The usual etiologic agent is *Aspergillus fumigatus*; however, *Aspergillus terreus* is just as fatal.⁵ A study by Shesiona et al found that *Aspergillus terreus* was the etiologic agent of invasive bronchopulmonary aspergillosis at a rate of 3-12.5%.⁵ High mortality and morbidity rates (98%) are found in immunocompromised patients with invasive aspergillosis (IA).²⁻⁸ *Aspergillus terreus* is a common cause of fungal infection in patients with hematologic (leukemia) malignancies and in recipients of solid-organ and hematopoietic stem-cell transplants.^{3,9} Caston et.al. conducted a review of 505 positive culture for filamentous fungi. Thirty-one percent of the patients had solid organ or stem cell transplants. Of this group, 59% had infections due to *Aspergillus fumigatus*, 9% due to *Aspergillus terreus*, and 8% due to *Aspergillus niger*. Additionally, 59% of the *Aspergillus terreus* isolates were associated with invasive infections.⁴ Steinbach et.al. reported that *Aspergillus terreus* was the most frequent cause of invasive pulmonary aspergillosis in patients with leukemia at a rate of 54%.⁷ In a study by Baddley et. al., 896 *Aspergillus* isolates were evaluated. Of these isolates, 60% were caused by *Aspergillus fumigatus*, 18% due to *Aspergillus niger*, 12% *Aspergillus terreus*, and 9% *Aspergillus flavus*. *Aspergillus terreus* isolates relative to the total number of isolates increased from 2% to 10%.⁸

Inhalation of airborne conidia provides a mode of transmission for *Aspergillus terreus*. However, in this case study, direct inoculation was the route of entry. The patient did not possess any of the known risk factors that include immunosuppression, host factors, and hospitalization.²

RESISTANCE FACTORS

Alveolar macrophages are typically the first line of defense against inhaled conidia. *Aspergillus terreus* conidia are phagocytosed more rapidly than other species possibly due to a higher exposure of beta-1,3 glucan and galactomannan on the surface. Once phagocytosed, the organism is still viable but is unable to germinate. This results in less damage to the macrophages via an inability to pierce the macrophages and to cause less cell damage. *Aspergillus terreus* is also able to survive in acidified phagolysosomes.⁵

Species of *Aspergillus* produce two types of asexual conidia - phialidic and accessory. One possible theory related to the resistance of *Aspergillus terreus* is the organism's ability to produce accessory conidia directly on the hyphae in vivo and in vitro. Accessory conidia possess the following characteristics: may enhance virulence, are smoother with a thicker outer cell surface with no apparent pigment-like layer, germinate rapidly, have enhanced adherence to macrophages, and are metabolically more active than phialidic conidia.⁹

Findings of a study by Deak et.al. demonstrated that all *Aspergillus terreus* isolates are able to produce accessory conidia but in different quantities and shapes.⁹ Phialidic conidia are not produced during infection while the detection of accessory conidia is considered diagnostic for *Aspergillus terreus*.⁹ As stated in Deak et. al., "...the findings of this study suggest a possible role for AC [accessory conidia] in *A. terreus* pathogenesis."⁹ This study also demonstrated *Aspergillus terreus* organisms contain less membrane ergosterol which correlates with decreased susceptibility to amphotericin B (AMB); thus, higher minimal inhibitory concentrations to AMB.⁸ However, in a study by Blum et.al. it was determined "...ergosterol content and cell wall composition do not play a crucial role in the AMB resistance of *A. terreus*."¹⁰ Thus, the resistance mechanism of *Aspergillus terreus* is still a topic of debate.

LABORATORY DATA

The ophthalmologist collected corneal scrapings that were submitted for aerobic and anaerobic bacterial and fungal cultures. The corneal scraping specimen was directly inoculated to media plates. No growth was reported with the aerobic and anaerobic bacterial cultures. At 48 hours, the initial report from the fungal culture indicated rare growth of mycelia fungal forms. The fungal cultures were sent to a reference laboratory for identification. The fungus was identified as *Aspergillus terreus* by phenotypic methods. No additional fungi were isolated after 4 weeks.

Traditional phenotypic identification procedures for fungi include macroscopic appearance on media and microscopic identification with lactophenol cotton blue stain. The macroscopic appearance of *Aspergillus terreus* is described as velvety, brown, cinnamon, buff or orange-brown often with radial folds. The reverse appearance is white to brown.¹¹ (Figure 1)

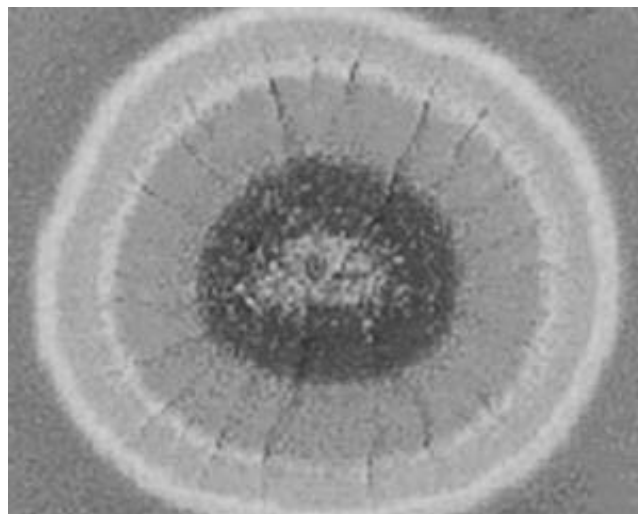


Figure 1. *Aspergillus terreus* colony morphology.

The microscopic appearance is noted as small vesicles (10-16 μ) that are dome shaped. Proximal (primary) phialides and shorter distal (secondary) phialides produce a "swept-forward" appearance. The smooth, elliptical conidia form long chains.¹¹ (Figure 2)

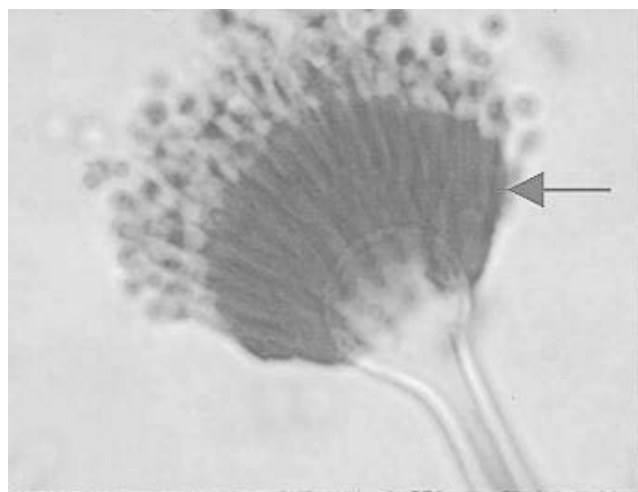


Figure 2. *Aspergillus terreus* microscopic morphology.

Fungal identification procedures may not always be routinely performed in a hospital laboratory setting due to small patient volumes or lack of technical competency. Therefore mycology studies may be performed in a reference laboratory as was the situation with this patient. Because microscopic morphology of fungal organisms is a definitive identification tool, it is vital that laboratory professionals performing such procedures demonstrate technical competency.

Definitive identification of fungal organisms is based on microscopic features such as shape, arrangement of

conidia and existing structures. These microscopic features are better visualized using the adhesive tape preparation with lactophenol cotton blue stain, a wet mount or a microslide culture.¹²

Genotypic methods are based on the detection of genetic material. Polymerase chain reaction methods are used to detect DNA, thus allowing detection of microorganisms directly from the specimen. PCR methods dramatically decrease the time to identify a fungus. One method employed is real time polymerase chain reaction (rt-PCR). Rt-PCR can be used to detect *Aspergillus spp.* directly from biological samples.¹³⁻¹⁴ Biological samples include: plasma or serum, lung samples, bronchoalveolar lavage specimens, sputum, aspirate fluid, thoracic puncture fluid, cerebral spinal fluid, liver tissue and pericardial exudate.¹³

Polymerase chain reaction uses the process of nucleic acid replication to make copies of the target nucleic acid – DNA. This involves three steps – denaturation, annealing of primers and primer extension. Denaturation causes the release of the nucleic acid target from the organism either by heat, chemicals or an enzyme. The target nucleic acid is denatured to a single strand. Primers are used to anneal to the nucleic acid target. Target copies, also referred to as amplicons, are measured using a labeled probe.¹²

Bolehovska et.al. conducted a study to “design a standard and reproducible *Aspergillus* DNA detection method and its validation.”¹³ One objective of this study was to develop a practical “method for diagnosis of *Aspergillus* DNA in various samples.”¹³ Real-time PCR was conducted using two hybridization probes. Specificity was determined using *Aspergillus fumigatus*, *Aspergillus flavus*, *Aspergillus niger*, and *Aspergillus terreus*. The rt-PCR technique was found to be of high sensitivity, specificity and reproducibility.¹³⁻¹⁴ Use of rt-PCR allows for a same day result.

ANTIMICROBIAL TREATMENT

The antifungal agent amphotericin B (AMB) has long been the drug of choice for treatment of fungal infections.¹⁵ However, *Aspergillus terreus* demonstrates resistance to AMB.¹⁵⁻¹⁸ Antifungal agents to be considered effective against *Aspergillus terreus* include the triazoles and echinocandins. The triazoles are synthetic compounds with one or more triazole ring

bound to an isobutyl core, e.g. voriconazole or carbon atom with lipophilic complex, e.g. itraconazole and posaconazole. The triazoles alter cell membrane function or inhibit cell growth and replication. The echinocandins consist of semisynthetic amphiphilic lipoproteins composed of a cyclic hexapeptide core linked to a N-acyl side chain, e.g. caspofungin, micafungin, and anidulafungin. The echinocandins inhibit (1-3) beta-D-glucan synthase (cell wall component).¹⁷

Antifungal triazoles are “synthetic compounds that have one or more triazole ring attached to an isobutyl core (e.g. voriconazole) or to an asymmetric carbon atom with a lipophilic complex mixed with functional aromatic chain (e.g. itraconazole and posaconazole).”¹⁷ Results from numerous studies indicate voriconazole is the drug of choice for treatment of fungal infections due to *Aspergillus terreus*.^{2,15-18} Voriconazole may be administered orally or intravenously (IV) and is FDA approved for primary treatment of invasive aspergillosis (IA).¹⁷⁻¹⁸ Advantages of using voriconazole include low minimal inhibitory concentrations (MICs) and decreased patient morbidity and mortality.¹⁵ Oral or parenteral administration of itraconazole is licensed for treatment of IA in patients that don't respond to standard treatment. Oral posaconazole is FDA approved for prevention of IA in patients receiving remission chemotherapy for a hematologic malignancy.¹⁷

Echinocandins are currently only available for IV administration. Caspofungin is indicated in patients with IA that do not respond appropriately to approved therapies. Micafungin and anidulafungin have activity against *Aspergillus* but have not been approved.¹⁷

CONCLUSION

This case demonstrates the ability of *Aspergillus* species to cause opportunistic infections in patients that do not demonstrate the usual host risk factors, i.e. immunosuppression, hospitalization, hematological malignancy or solid organ transplant. While *Aspergillus flavus* (9-16%) and *Aspergillus fumigatus* (60-67%) are the more commonly isolated species, *Aspergillus terreus* is increasingly being identified as the causative agent of fungal infections.⁴⁻⁸ The previously cited studies confirm the increased prevalence of *Aspergillus terreus* (9-10%) with a 54% recovery rate in patients with leukemia that have developed invasive pulmonary aspergillosis.⁷⁻⁸

Aspergillus terreus isolates are more likely to cause disseminated and fulminating infections thus resulting in higher mortality and morbidity rates (98%) especially in immunocompromised patients.⁵

The expertise of the laboratory professionals was vital to the positive outcome for this patient. Recognition of fungal elements on the initial fungal culture resulted in the addition of an antifungal agent to the treatment regimen. Timely identification of the etiologic agent as *Aspergillus terreus* and antimicrobial susceptibility information indicating increased MICs for amphotericin B for this organism resulted in appropriate selection of an effective antifungal agent.

Traditional laboratory methods for identification of fungi are based on phenotypic characteristics such as macroscopic and microscopic morphology. However, genotypic methods have been developed to identify the organism utilizing PCR to detect genetic material. PCR techniques demonstrate high sensitivity and specificity for *Aspergillus terreus* and allow for same day identification of the organism.

Aspergillus terreus produces both phialidic and accessory conidia. Studies provide evidence that the accessory conidia are a resistance factor for the organism. The detection of accessory conidia is considered diagnostic for *Aspergillus terreus*.

Resistance to AMB is found with *Aspergillus terreus*. Therefore, treatment recommendations include antifungal agents from the triazole and echinocandins categories. Numerous studies indicate that voriconazole is the drug of choice for treatment of infections due to this microorganism.¹⁵⁻¹⁸

In this case, the mode of transmission and infection site demonstrates the ability of *Aspergillus terreus* to cause infections outside of the more commonly seen pulmonary infections and invasive aspergillosis. Clinicians and laboratory professionals should be aware of the increased recovery of *Aspergillus terreus* as the causative agent of fungal infections.

REFERENCES

1. <http://dictionary.reference.com/browse/hypopyon>. Accessed 25 August 2013.
2. <http://www.cdc.gov/fungal/aspergillosis/> Accessed 12 June 2012. Page last updated January 9, 2012.
3. Ozer B, Kalaci A, Duran N, Dogramaci Y, Yanat AN. Cutaneous infection caused by *Aspergillus terreus*. J Med Microbiol 2009;58(7):968-70.
4. Caston, JJ, Linares, MJ, Gallego C, Rivero A, Font P, Solis, F, et al. Risk factors for pulmonary *Aspergillus terreus* infection in patients with positive culture for filamentous fungi. Chest 2007;131(1):230-6.
5. Steinbach WJ, Benjamin DK, Kontoyannis DP, Perfect JR, Putsar I, Marr KA, et al. Infections due to *Aspergillus terreus*: a multicenter retrospective analysis of 83 cases. Clin Infect Dis 2004;39(2):192-8.
6. Slesiona S, Gressler M, Mihlan M, Zaehle C, Schaller M, et al. Persistence versus escape: *Aspergillus terreus* and *Aspergillus fumigatus* employ different strategies during infections with macrophages. PLoS ONE 2012;7(2):e31223.
7. Steinbach WJ, Perfect JR, Schell WA, Walsh, TJ, Benjamin, DK. In vitro analyses, animal models, and 60 clinical cases of invasive *Aspergillus terreus* infection Antimicrob Agents Chemother. 2004;48(9):3217-25.
8. Baddley JW, Pappas PG, Smith AC, Moser SA. Epidemiology of *Aspergillus terreus* at a university hospital. J Clin Microbiol 2003;41(12):5525-9.
9. Deak E, Wilson SD, White E, Carr JH, Balajee SA. *Aspergillus terreus* accessory conidia are unique in surface architecture, cell wall composition and germination kinetics. PLoS ONE 2009;4(10):e7673.
10. Blum G, Perkhofers S, Haas H, Schrettl M, Reinhard W, Dierich M, Lass-Flörl C. Potential basis for amphotericin B resistance in *Aspergillus terreus*. Antimicrobial Agents and Chemotherapy April 2008;1553-5.
11. Koneman, E. The Koneman mycology atlas and guide. Colorado Association for Continuing Medical Laboratory Education. 2013.
12. Laboratory Methods in Basic Mycology. In Forbes B, Sahn D, Weissfeld A. Bailey and Scotts Diagnostic Microbiology 12th ed. St. Louis, MO. Mosby Elsevier: 2007:629-716.
13. Bolehovska R, Pliskova L, Buchta V, Cerman J, Hamal P. Detection of *Aspergillus* spp. in biological samples by real-time PCR. Biomed Pap Med Fac Univ Palacky Olomouc
14. Rameriz M, Castro C, Palomares JC, Torres MJ, Aller AI, Ruiz M, et al. E. Molecular detection and identification of *Aspergillus* spp. from clinical samples using real-time PCR. Mycoses 2009Mar;52(2):129-34.
15. Sutton DA, Sanche SE, Revankar SG, Fothergill AW, Rinaldi MG. In vitro amphotericin B resistance in clinical isolates of *Aspergillus terreus*, with a head-to-head comparison to voriconazole. J Clin Microbiol 1999;37(7):2343-5.
16. Hachem RY, Konoyiannis DP, Boktour MR, Afif C, Cooksley C, Bodey G, et al. *Aspergillus terreus*: an emerging amphotericin B-resistant opportunistic mold in patients with hematologic malignancies. Cancer 2004;101(7):1594-600.
17. Walsh TJ, Anaissie EJ, Denning DW, Herbrecht R, Kontoyiannis DP, Marr KA, et al. Treatment of aspergillosis: clinical practice guidelines of the infectious disease society of America. Clin Infect Dis 2008;46:327-60.
18. Peman J, Salavert M, Canton E, Jarque I, Roma E, Zaragoza R, et al. Voriconazole in the management of nosocomial invasive fungal infections. Therapeutics and Clinical Risk Management 2006;2(2):129-58.