

Differentiating the Dermatophytes

JEREMY R CADDELL

ABBREVIATIONS: KOH = potassium hydroxide; PDA = potato-dextrose agar.

INDEX TERMS: dermatophytes; fungus

Clin Lab Sci 2001 15(1):13

Jeremy R Caddell is a Clinical Laboratory Scientist at Mayo Foundation, Rochester MN.

Address for correspondence: Jeremy R Caddell CLS (NCA), Mayo Foundation, 200 1st St SW, Rochester MN 55905. (507) 284-3036, (507) 284-0071 (fax). Caddell.Jeremy@Mayo.edu

Dermatophytosis is one of the most common communicable diseases in the world.¹ Dermatophytes are fungi whose primary sites of infection are hair, skin, and nails.² The identification of dermatophytes is clinically important because of the various infections that they can cause.³ Among some of the more common and difficult diseases are Tinea capitis, Tinea unguium, Tinea barbae, and Tinea pedis.

Tinea capitis is a form of ringworm that most commonly infects the scalp. It can cause ulcers on the scalp of the patient and loss of hair. Tinea unguium is a form of ringworm that most commonly infects fingernails and toenails. It can cause the patient's nail to become brittle, cracked, and crumbly. Tinea barbae is an infection of the bearded area of the face and neck of adult males. It can cause lesions with severe inflammation and extensive hair loss. Tinea pedis is the most common dermatophyte infection and infects the feet. It can cause the affected area of the feet to become pruritic with peeling of the foot tissue.

Since dermatophytes only invade the keratinized layers of hair, skin, and nails, clinical material must be obtained properly and can be sent to the laboratory for culture and direct examination. Direct examination of clinical material from patients with dermatomycosis can aid in the diagnosis and treatment of the patient.⁴ A piece of the clinical material from a patient can be ob-

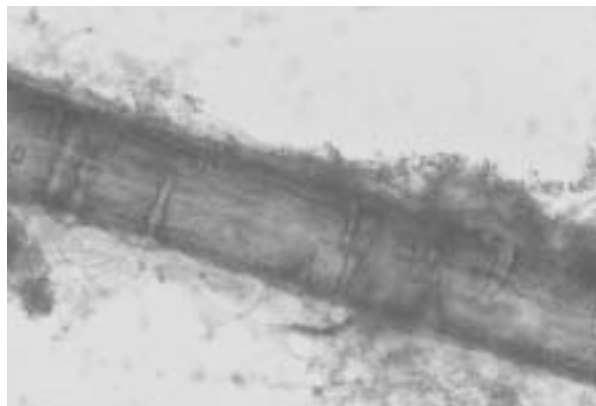
The peer-reviewed Clinical Practice section seeks to publish case studies, reports, and articles that are immediately useful, of practical nature, or demonstrate improvement in the quality of laboratory care. Direct all inquiries to Bernadette Rodak MS CLS(NCA), CLS Clinical Practice Editor, Clinical Laboratory Science Program, Indiana University, Fesler 409, 1120 South Avenue, Indianapolis, IN 46202-5113.; or send e-mail to brodak@iupui.edu

served in a potassium hydroxide (KOH) preparation at the same time it is cultured. If hyphae are seen in the KOH prep the patient's physician can be notified that a fungal infection is occurring days before the fungus will grow in culture and therefore treatment can be started immediately.

There are two laboratory tests used to help distinguish dermatophyte organisms from each other. When inoculated onto a urea slant some organisms will produce urease which will break down the urea in the slant changing the pH that causes the phenol red indicator in the slant to change from yellow to red. If the color changes within three days the test is considered positive.

The hair perforation test consists of inoculating colonies of an organism into a dish containing a small amount of water, a few drops of yeast extract solution, and some human hair. Incubate the dish at 30 °C and after seven days take some of the hair, put it on a slide with a cover slip, and observe it under the microscope. The test is considered positive if the hair has deep, narrow wedge-shaped perforations in it (Figure 1).

Figure 1. Positive hair perforation test.



Five common dermatophytes that are identified at the Mayo Clinic Mycology Laboratory are *Microsporum gypseum*, *Microsporum canis*, *Trichophyton rubrum*, *Trichophyton mentagrophytes*, and *Trichophyton tonsurans*.

Microsporum gypseum is most commonly isolated from the hair or scalp. The fungus grows rapidly and morphologically the colonies will appear powdery on potato-dextrose agar (PDA) due to the large

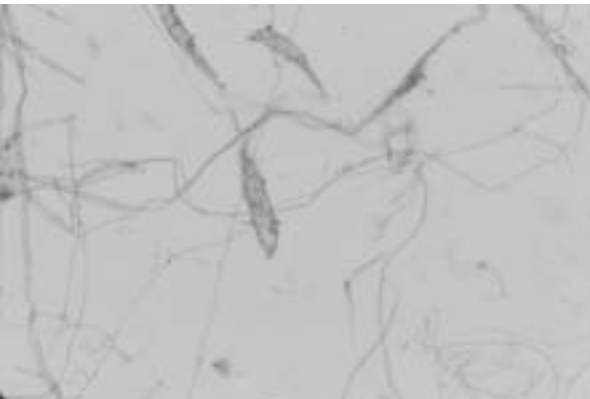amount of conidia that are produced. The colonies have a cinnamon to brown color with ragged or scalloped edges on PDA.⁵ The macroconidia have rough walls that are thin, have rounded ends, and have six or fewer centrally constricted septa (Figure 2).⁶ The urease and hair perforation tests are both positive for this organism.

Figure 2. *Microsporum gypseum*



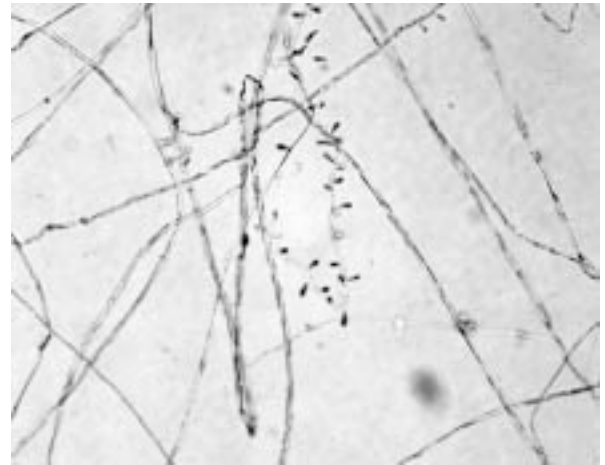
Microsporum canis is most commonly isolated from the hair or scalp, and is one of the most common causes of ringworm. The majority of infections occur in children who acquire the organism through contact with an infected animal, usually a cat or a dog. The fungus grows rapidly and morphologically appears woolly or fluffy. The colonies have a bright-yellow pigment around the outer edge and on the reverse on PDA. The macroconidia have thicker walls than *M. gypseum* and have a minimum of six septa. The ends of the macroconidia are narrowed whereas the ends of *M. gypseum* are rounded (Figure 3). The urease and hair perforation tests are both positive for this organism.

Figure 3. *Microsporum canis*



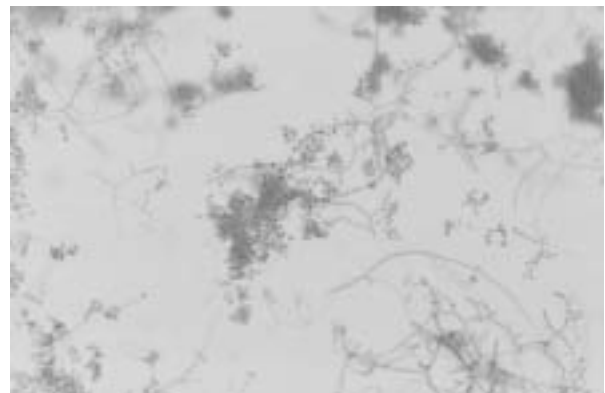
Trichophyton rubrum is the most common dermatophyte to infect humans. It primarily infects the skin and nails. Morphologically, the colony is white and fluffy while the reverse of the colony will be red on PDA. Microscopically, teardrop-shaped microconidia are found along the hyphae (Figure 4). The urease and hair perforation tests are both negative for this organism. *T. rubrum* will have 4+ growth on Trichophyton agar No. 1 that has a casein base.⁷

Figure 4. *Trichophyton rubrum*



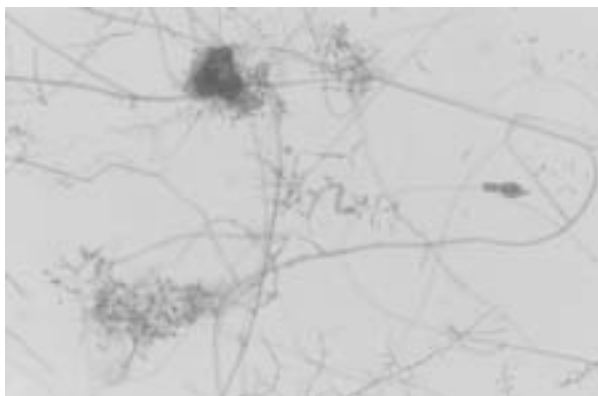
Trichophyton mentagrophytes invades feet primarily and is a common cause of athlete's foot. Morphologically, the colony is white and powdery and the reverse color can be variable on PDA. Microscopically, the microconidia are round and they are found in clusters (Figure 5). The urease and hair perforation tests are both positive for this organism. *T. mentagrophytes* will have 4+ growth on Trichophyton agar No. 1.⁸

Figure 5. *Trichophyton mentagrophytes*



Trichophyton tonsurans is an organism that primarily invades the scalp. Morphologically, the colony is brown and suede-like and the reverse is reddish-brown on PDA. Microscopically, the microconidia are club-shaped and are perpendicular to the hyphae (Figure 6). The microconidia can become enlarged and are then referred to as 'balloon' forms. The urease test is positive and the hair perforation test is negative. *T. tonsurans* will have +/- or 1+ growth on Trichophyton agar No. 1.⁹

Figure 6. *Trichophyton tonsurans*



There are many reasons why the accurate identification of dermatophytes is clinically important. Some patients may have a dermatophyte infection that is nonpathogenic and the patient may not need treatment, whereas other patients may have a dermatophyte infection that does need treatment. If left untreated the dermatophyte infection can cause inflammation of the patient's skin and possible scarring. The longer that a patient has a dermatophyte infection, the greater the risk of transmission to another person. Also, identifying the organism can help determine the reservoir of the infection to determine if it is associated with an animal, or possibly a hospital or daycare center.

REFERENCES

1. Kane J, Summerbell R, Sigler L, and others. Laboratory handbook of dermatophytes. Belmont CA: Star Publishing Company; 1997. p 1.
2. Kane, Summerbell, Sigler, and others. Laboratory handbook of dermatophytes. Belmont CA: Star Publishing Company; 1997. p 5.
3. Kane, Summerbell, Sigler, and others. Laboratory handbook of dermatophytes. Belmont CA: Star Publishing Company; 1997. p 6.
4. James T. Sinski. Dermatophytes in human skin, hair and nails. Springfield IL: Charles C Thomas; 1974. p ix.
5. Kane, Summerbell, Sigler, and others. Laboratory handbook of dermatophytes. Springfield IL: 1997. Charles C Thomas; p 202.
6. Kane, Summerbell, Sigler, and others. Laboratory handbook of dermatophytes. Springfield IL: Charles C Thomas; 1997. p 203.
7. Larone DH. Medically important fungi. Washington DC: ASM Press; 1995. p 172-3.
8. Larone DH. Medically important fungi. Washington DC: ASM Press; 1995. p 171-2.
9. Larone DH. Medically important fungi. Washington DC: ASM Press; 1995. p 172, 174.

TEXAS – Faculty Position

MASTER OF SCIENCE IN MOLECULAR PATHOLOGY PROGRAM

Department of Diagnostic and Primary Care
 School of Allied Health
 Texas Tech University Health Sciences Center

Twelve-month, tenure-track faculty position in the Department of Diagnostic and Primary Care, with a joint appointment in the Department of Pathology within the School of Medicine. Doctorate, with clinical certification in molecular biology preferred. MT(ASCP) or CLS(NCA) certification a plus. Candidate must have experience in diagnostic molecular techniques and demonstrate ability to teach at the undergraduate and graduate level (including pathology residents), supervise graduate students, and participate in research activities in the School of Allied Health and School of Medicine. Laboratory facilities and equipment are new and dedicated to molecular pathology activities. The Texas Tech University and TTU Health Sciences Center campus is located in the Lubbock metropolitan area with a population of 230,000, a diversified economy, and a thriving healthcare industry. The quality of life is excellent.

Send cover letter and curriculum vita to:

Lori Rice-Spearman MS, Department of Diagnostic and Primary Care, TTUHSC, 3601 4th Street Mail Stop 6281, Lubbock TX 79430. (806) 743-3255. lori.rice-spearman@ttmc.ttuhs.edu