

Strongyloidiasis: A Review and Update by Case Example

KATHERINE GREINER, JOSEPH BETTENCOURT, CAROLE SEMOLIC

A 77-year-old female immigrant from South America presented with epigastric pain, diarrhea, gastrointestinal bleeding, malabsorption, and acid reflux disorder. A gastroduodenoscopy, performed to assess for peptic ulcer disease, revealed parasitic larvae in the duodenal mucosa which were subsequently identified as *Strongyloides stercoralis* rhabditiform larvae. Anti-helminthic therapy was initiated to resolve infection.

OBJECTIVES: Review the pathogenesis, diagnosis and treatment of strongyloidiasis; alert laboratory professionals to the importance of early detection of *Strongyloides stercoralis* in specimens from immigrants at risk and immunodeficient patients to reduce morbidity and mortality.

ABBREVIATIONS: AIDS = acquired immunodeficiency syndrome; EIA = enzyme immunoassay; HIV = human immunodeficiency virus; HTLV-1 = human T-cell lymphotropic virus type 1; IgE = immunoglobulin E; IgG = immunoglobulin G.

INDEX TERMS: hyperinfection; immunodeficiency disorders; rhabditiform larvae; strongyloidiasis.

Clin Lab Sci 2008;21(2):82

Katherine Greiner MS MT (ASCP) is associate professor, Department of Medical Laboratory Sciences (Clinical Microbiology, Clinical Immunology/Immunohematology), Marist College, Poughkeepsie NY.

The peer-reviewed Clinical Practice Section seeks to publish case studies, reports, and articles that are immediately useful, are of a practical nature, or contain information that could lead to improvement in the quality of the clinical laboratory's contribution to patient care, including brief reviews of books, computer programs, audiovisual materials, or other materials of interest to readers. Direct all inquiries to Bernadette Rodak MS CLS(NCA), Clin Lab Sci Clinical Practice Editor, Clinical Laboratory Science Program, Indiana University, Clarian Pathology Laboratory, 350 West 11th Street, 6002F, Indianapolis IN 46202. brodak@iupui.edu

Joseph Bettencourt PhD is associate professor, Department of Biology (Parasitology, Immunology, Anatomy), Marist College, Poughkeepsie NY.

Carole Semolic MT is medical technologist, Microbiology Department, St. Luke's Cornwall Hospital, Newburgh NY.

Address for correspondence: Katherine Greiner MS MT (ASCP), associate professor, Department of Medical Laboratory Sciences (Clinical Microbiology, Clinical Immunology/Immunohematology), Marist College, DN 228, 3399 North Road, Poughkeepsie NY 12601. (845) 575-3000, ext. 2505, (845) 575-3184 (fax). Katherine.Greiner@Marist.Edu.

CASE HISTORY

A 77-year-old female immigrant from South America sought medical attention at a hospital clinic due to epigastric pain and diarrhea. She was diagnosed with gastrointestinal bleeding, malabsorption, and acid reflux disorder coupled with possible ulceration of the esophagus. A gastroduodenoscopy was performed to determine if she had peptic ulcer disease. Recommendations for stool analysis were made based on the histopathology findings.

LABORATORY RESULTS

Biopsies of the small intestine and esophageal-gastric junction were taken. The mucosa of the small intestine was hyperemic and characterized by areas of acute or chronic inflammation. The gastric mucosa of the fundus also was hyperemic and had focal areas of mild, nonspecific, chronic inflammation. Focal metaplasia, suggestive of Barrett's esophagus, was seen in the esophageal mucosa. There was no evidence of ulceration, granuloma formation, or malignancy.

Cross-sections of structures resembling parasitic larvae were prominent in the duodenal histologic preparations. Subsequent stool analysis confirmed that these forms in sectioned tissue were *Strongyloides stercoralis* larvae. The larvae were observed in the mucosal region of the duodenum, within the lumen of the crypts of Lieberkuhn (Figure 1). Typically, the crypts are invaded by juvenile or adult forms of *Strongyloides stercoralis*.

Three stools for ova and parasite studies were submitted to the laboratory the following week. Trichrome stains on smears prepared from stool concentrates on all three specimens were negative for protozoa but revealed *Strongyloides stercoralis* rhabditiform larvae. Two fecal smears had many larvae present while the third showed only a few.

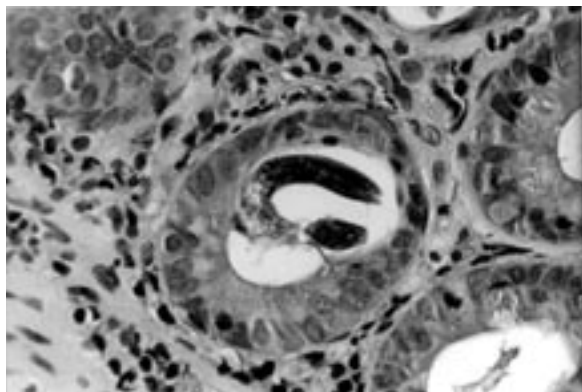
A diagnosis of strongyloidiasis was made on the basis of rhabditiform larval morphology. Larvae were characterized by a short buccal cavity, a sharply pointed tail, and the presence of a noticeable midsection genital primordium. *Strongyloides* ova are a rare finding in fecal smears and were not seen on the slides reviewed.

LIFE CYCLE

Strongyloides stercoralis is a member of the order Rhabditida which includes tiny round worms which bridge the gap between free-living and parasitic modes of life. Within this order, *Strongyloides stercoralis* is the most common, widespread species of medical importance in humans and other primates but also infects other mammals like dogs and cats.

Humans acquire strongyloidiasis through soil, food, or water contaminated with infectious larvae. Invasive third-stage, filariform larvae (490 μ m-630 μ m) can directly penetrate skin from soil or be ingested in contaminated food or water (Figure 2). The site of skin entry is usually exposed areas on the hands, feet, and buttocks. Invasive juveniles that burrow into the skin are transported to the lungs by the bloodstream, where they migrate from pulmonary capillaries to alveolar spaces. Upward

Figure 1. *Strongyloides stercoralis* rhabditiform larva in the lumen of a crypt of Lieberkuhn. 430X



movement from the lungs to the respiratory airways causes irritation. Juveniles are coughed up to the pharynx and then swallowed, eventually lodging in the intestine. Lung migration is unnecessary if juveniles in food or water are directly swallowed and conveyed to the small intestine.

In the small intestine filariform larvae molt twice, developing into adult female parasites (2 mm-3 mm). Females anchor into the intestinal mucosa with their mouths or thread their anterior ends into the submucosa. They produce several dozen, thin-shelled eggs per day through parthenogenesis.

Eggs are released into the intestinal lumen or submucosa and hatch during transit through the gut or while in the submucosa. Juveniles escaping from the eggs develop into first stage larvae called rhabditiform larvae (300 μ m -380 μ m) which are passed from feces to soil. The rhabditiform larvae become infective third-stage filariform larvae after two more stages of development in soil and are capable of infecting a new host if directly contacted or ingested.

Autoinfection can occur and represents a permutation of the life cycle. If first stage juveniles molt twice during transit down the intestinal tract, they become infective filariform larvae that can penetrate the lower gut mucosa (internal autoinfection) or perianal skin (external autoinfection) and begin migration to the lungs and up the respiratory tree to the pharynx, ultimately returning to the small intestine. Autoinfection occurs at a significant rate in states of immunosuppression and appears to contribute to the life-threatening hyperinfections seen in individuals with immunocompromising illness. Whether by continuance of adult worms in the small intestine or by autoinfection, some cases of strongyloidiasis have resulted in persistent infection lasting for decades.

In the free-living life cycle of *Strongyloides stercoralis*, rhabditiform larvae can molt to the fourth stage of development in soil, maturing into free-living adult males and females. Adult worms mate, resulting in egg release from which new rhabditiform larvae emerge. These hatched larvae then either develop into free-living adult worms or into filariform larvae that infect humans.

SYMPTOMS

Disease severity varies in strongyloidiasis. Numerous cases originating in endemic areas are chronic and asymptomatic when immunocompetency exists. Some individuals are evaluated for parasitosis on the basis of unexplained eosinophilia

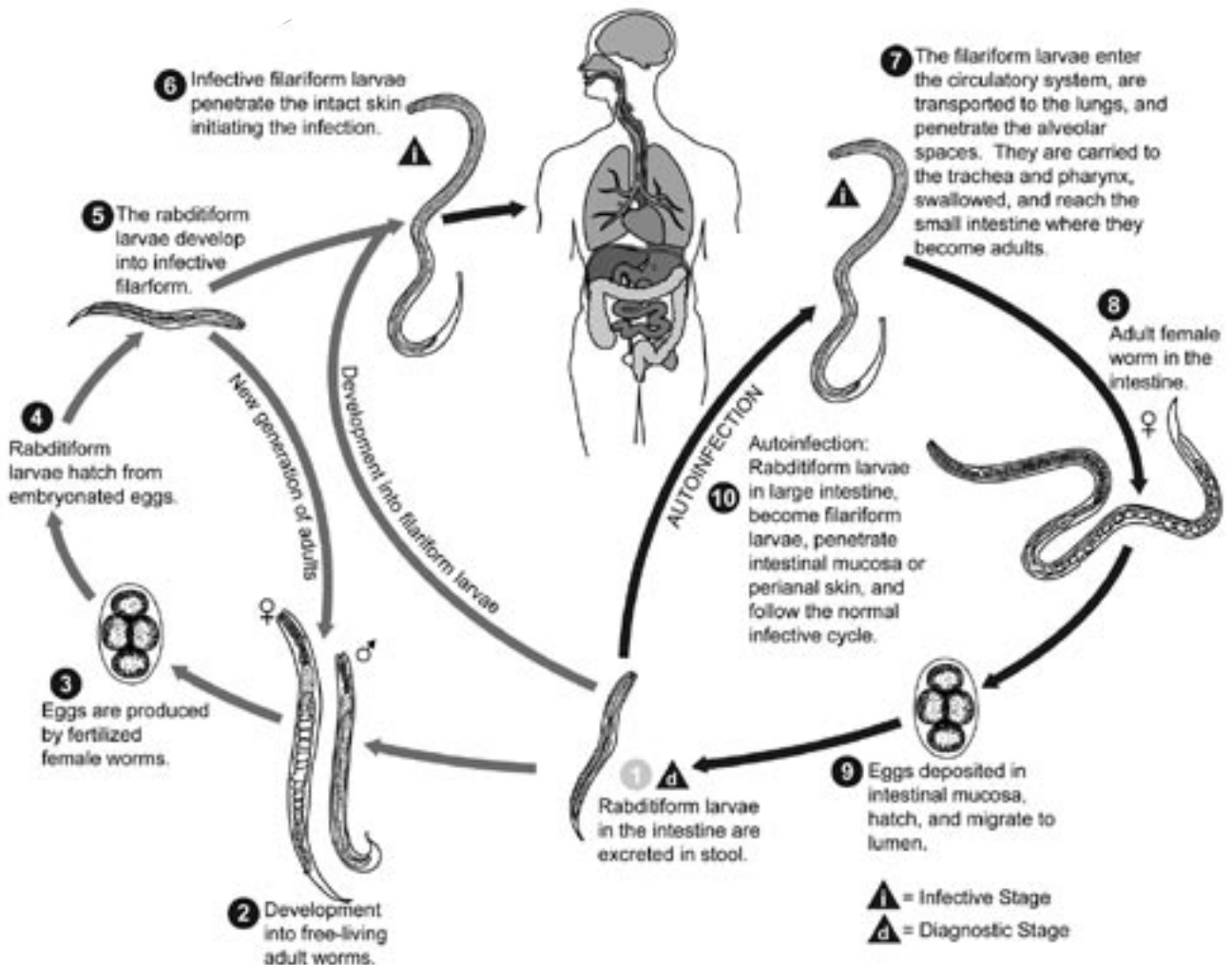
only. The more complex cases are characterized by symptomatology resulting from higher numbers of parasites in skin, lung, and gastrointestinal tissue.

Dermatologic involvement at filariform points of entry is manifested by a migrating, urticarial, erythematous rash, termed larva currens. Larva currens occurs more often in the skin of the buttocks, groin, and trunk than that of the extremities. Eruptions may be particularly prominent in perianal sites where the external autoinfection cycle begins.

Pulmonary migration phases are associated with coughing, wheezing, and shortness of breath, symptoms which may lead to a diagnosis of asthma and treatment with steroid-based medications that potentiate more extensive parasite invasion.

Epigastric pain and abdominal tenderness, along with bloating, nausea, anorexia, and diarrhea are general signs of gastrointestinal invasion. A potentially fatal outcome is associated with massive hyperinfection due to autoinfection cycles. Compli-

Figure 2. Life cycle of *Strongyloides stercoralis*



CDC Public Health Image Library, ID#: 3419. Available from <http://phil.cdc.gov/phil/home.asp>. Content providers: CDC/Alexander J. da Silva, PhD/Melanie Moser

cated strongyloidiasis is associated with colitis and ulceration of the intestinal mucosa with resulting bowel perforation.

LABORATORY DIAGNOSIS

The primary detection method for *Strongyloides stercoralis* remains stool examination whereby first-stage rhabditiform larvae can be demonstrated in freshly passed specimens. A direct fecal exam, preferably done with saline-Lugol iodine stain, is effective in diagnosing the less frequent cases of massive infection. However, in uncomplicated infection the parasite load in specimens is usually low, requiring examination of stool that has been concentrated by the formalin-ethyl acetate technique. Mild to moderate eosinophilia^{1,2} may be the only clue that parasite infection exists when stools are negative, indicating that further testing on stool should be done. Low worm loads and day-to-day variability in the shedding pattern of juveniles raise the level of difficulty in detecting larvae in most cases of strongyloidiasis. Multiple examinations of stool significantly improve diagnostic sensitivity.^{3,4} Rarely, embryonated eggs can be seen in stools from patients who are experiencing severe diarrhea or from whom specimens have been collected with purgation.

The inherent difficulty in identifying *Strongyloides stercoralis* in stool specimens relates to the morphologic similarities that exist between the ova and rhabditiform larvae of *Strongyloides* and the ova and rhabditiform larvae of hookworms. The hookworms, *Necatur americanus* and *Ancylostoma duodenale*, also are nematodes which parasitize the small intestine. Their impact on humans is generally more severe because they feed

on blood and tissue fluids after invading the mucosal lining, causing iron deficiency anemia and hypoproteinemia.

Strongyloides infection is diagnosed by detection of rhabditiform larvae in fecal material. In contrast, hookworm infection is diagnosed by demonstrating ova in stool, which are routinely excreted, or the adult male and female worms which can be recovered after antihelminthic treatment. In hookworm infection, however, eggs can hatch in stool as a result of constipation or delayed examination, yielding rhabditiform larvae which bear close resemblance to *Strongyloides* rhabditiform larvae and are confused with them. Detection of *Strongyloides* larvae can be further complicated if patients are dually infected with both *Strongyloides* and hookworms.


While the ova of *Strongyloides stercoralis* and hookworms are too similar to practically differentiate, the rhabditiform larvae of the two nematodes can be distinguished from each other. The buccal cavity of *Strongyloides stercoralis* larvae is short, being one-third to one-half the width of the head (Figure 3) while the buccal cavity of hookworm larvae is slightly longer than the width of the head. The genital primordium is large and usually visible in *Strongyloides* rhabditiform larvae but not readily apparent in hookworm rhabditiform larvae. In addition, the esophagus of *Strongyloides* rhabditiform larvae is hourglass-shaped and characterized by a posterior esophageal bulb.

In addition to histologic examination of duodenal tissue, duodenal aspirate evaluation increases the probability of detecting rhabditiform larvae to 60%-70%.⁵ Wet mount preparations of centrifuged duodenal fluid without preservative are examined within one hour of collection. Due to the invasive nature of duodenal aspiration, collection of duodenal fluid is generally reserved for rapid diagnosis in children suspected of heavy worm infestation or immunocompromised patients.

Pulmonary strongyloidiasis is often diagnosed with examination of wet preparations of sputum, bronchial washings and brushings, bronchoalveolar lavage fluid, or pleural fluid. Gram, acid-fast, and Papanicolaou stains all enhance detection of *Strongyloides* larvae.^{3,6,7}

A few other techniques can be used to detect *Strongyloides* larvae but are not typically done in diagnostic laboratories. The Baermann method and the Harada-Mori filter paper technique are based on larval migration during incubation.^{3,8} In the Baermann method, larvae migrate from fecal material

Figure 3. *Strongyloides stercoralis* rhabditiform larva in a fecal smear with the short buccal cavity evident. 430X



on gauze that lines a funnel containing warm water. Larvae move into the warm water and are collected by centrifugation. The Harada-Mori technique employs filter paper inoculated with fecal material which absorbs water in a test tube by capillary action during 30°C incubation. Larvae can be discerned at the sides of the filter paper after migration during incubation.

Agar plate culture is particularly effective in detecting *Strongyloides* larvae.^{3,8,9,10} Agar plates are inoculated with stool or duodenal fluid and incubated for two days at room temperature. Larvae crawl on the agar and spread bacteria in their paths, creating bacterial growth patterns on the agar surface. Larvae can be seen with microscopic examination of the plates and their presence confirmed with formalin washing of the plate surface and examination of the sediment from the washing.

Diagnosis of strongyloidiasis by enzyme immunoassay (EIA) serology has proven somewhat useful in immunocompetent individuals.² The EIA for detecting *Strongyloides stercoralis* infection detects immunoglobulin G (IgG) to filariform larvae. A major drawback to EIA evaluation for infection is that specificity is compromised when cross-reactive antibodies are present from other helminth infections like hookworm infection, filariasis, *Ascaris lumbricoides* infection, and acute schistosomiasis.^{3,11} As with many infections, antibodies can be detectable for years after treatment and it is often difficult to differentiate between past and current infection. The EIA can be of value, however, as a screening test. Negative test results in immunocompetent individuals suggest infection is unlikely while positive results warrant further assessment for parasites.

TREATMENT

The anthelmintic agents thiabendazole, albendazole, and ivermectin are used to treat strongyloidiasis. Thiabendazole has been associated with a relapse of infection and gastrointestinal side effects. Albendazole is a broad-spectrum anthelmintic drug which is safe and effective in treating *Strongyloides stercoralis* infection. Research indicates that it would be a useful, low-cost, medication to presumptively administer to immigrants at risk for parasitosis to reduce overall healthcare costs due to parasitic infection, annually, in the United States.¹² Ivermectin is a favored drug for treatment of strongyloidiasis because it is fairly well tolerated and associated with a high cure rate. It is very effective in treating both uncomplicated and complicated strongyloidiasis but more costly and limited in its range of activity against helminths than albendazole.

DISCUSSION

Strongyloidiasis is one of the most difficult parasitic diseases to diagnose due to a general absence of distinctive ova in stool specimens and a rarity of larval forms, particularly in uncomplicated cases. The life cycle of *Strongyloides stercoralis* also is one of the most complex of the helminthic cycles due to both parasitic and free-living forms and parthenogenic and autoinfection factors.

The ability to recognize *Strongyloides stercoralis* rhabditiform larvae in specimens is particularly important now due to increased immigration from areas of the world endemic for strongyloidiasis and the impact that immunodeficiency states have on *Strongyloides stercoralis* infection. Immunodeficiency predisposes the host to potentially massive, fatal infection with both parasites and bacteria. Heavy worm infestation of the intestinal wall causes ulceration of the mucosa producing symptoms suggestive of a duodenal ulcer or ulcerative colitis. Mucosal perforation can produce secondary, widespread bacterial sepsis that often causes fatality. Hyperinfection, which involves the gastrointestinal tract and lungs, can progress to disseminated or fulminant strongyloidiasis with parasite infestation of the liver, heart, adrenals, pancreas, kidneys and central nervous system.

Strongyloidiasis affects more than 30 million people worldwide.³ It is endemic in tropical regions and found under the same climatic and sanitary conditions favorable to hookworm infection. With immigration to the US reaching record highs over the past century, hundreds of thousands of immigrants have come to the US each year from such regions.¹² Those at higher risk for strongyloidiasis have immigrated from countries in Central and South America, the Caribbean, sub-Saharan Africa, Asia, Southeast Asia and the Middle East, many of which are experiencing an explosive spread of acquired immunodeficiency syndrome (AIDS). In the US strongyloidiasis is endemic in the southeast and has been well documented in the mentally disabled, many of whom are institutionalized.^{13,14,15} International travel poses a risk for Americans with immunosuppression who tour countries endemic for strongyloidiasis.

Strongyloidiasis is one of the primary causes of death in the US due to helminths.³ Complicated infection typically affects those with altered immune responses and occurs with malnutrition, high dose corticosteroid therapy, anti-cancer therapy, transplant therapy, malignancies, congenital immunodeficiencies and infections with human T-cell lymphotropic virus type 1 (HTLV-1), and human immunodeficiency virus (HIV).

The immune response to *Strongyloides stercoralis* is poorly understood but eosinophils and immunoglobulin E (IgE) seem to help limit infection with it to the intestine. Eosinophilia is a useful marker for infection and eosinopenia is correlated with a poor clinical outcome in fulminant infection.¹⁶ Defective T-cell responses coupled with autoinfection cycles account for heavy worm burdens in some immunosuppressed individuals and lead to hyperinfection syndrome and disseminated strongyloidiasis.

There is a strong correlation between *Strongyloides stercoralis* hyperinfection and HTLV-1 where both cause endemic infection, such as in southern Japan and the Caribbean.¹⁷ Co-infection with *Strongyloides stercoralis* and HTLV-1 is associated with treatment failure related to dysfunctional immune responses.^{18,19} A high level of interferon gamma is produced, and little interleukin 4, causing a reduction in IgE²⁰ which is needed for vasoactive effects in the intestine to assist in the expulsion of helminths. The immunomodulatory effect caused by HTLV-1 thus potentiates hyperinfection with *Strongyloides*. Testing for HTLV-1 is sometimes recommended for patients hyperinfected with *Strongyloides* who are refractory to standard antihelminthic treatment.

Diarrhea caused by intestinal parasitosis is prominent in AIDS and is related to impaired immunologic defense mechanisms along the intestinal mucosa. The prevalence of specific parasites appears to vary from country to country.²¹ While strongyloidiasis is not considered to be one of the more significant presenting opportunistic infections in AIDS^{22,23} HIV positive patients affected by it are at high risk for dissemination of infection and treatment failure.²⁴ It can be transmitted through anal sex and via oral contact and is associated with a lack of eosinophilia and poor IgE response.^{23,24,25} Individuals with AIDS often have additional risk factors which intensify *Strongyloides* infection such as treatment with corticosteroids, mycobacterial disease, malignancy and malnutrition.

CONCLUSION

This patient was treated with antihelminthic agents to relieve her gastrointestinal symptoms. Long-term follow-up was not possible due to a treatment plan offered through outpatient services at the hospital clinic.

In the majority of cases, a diagnosis of strongyloidiasis can be made in the clinical laboratory by microscopic examination of stool, tissue, and body fluids. The special tests that provide supplemental information about *Strongyloides stercoralis*

infection are economically impractical to perform even in the best of laboratories. They are sporadically needed and their overall use does not justify their cost and the additional personnel training required in order to perform them.

Molecular-based tests would facilitate the detection of strongyloidiasis and other parasitic infections by increasing sensitivity and specificity levels in testing but are currently not well-developed for clinical parasitology. They are used for a small number of parasite infections like *Trichomonas vaginalis* infection, babesiosis, and toxoplasmosis.⁸ Immunodiagnostic tests continue to be used as primary back-up assays to confirm parasitosis. However, mailing specimens with medical histories to the limited number of reference laboratories that perform them and obtaining test results can be a lengthy process.

Immigration from developing countries and a prevailing increase in immunodeficiency disorders throughout the world, particularly AIDS, has heightened an awareness of parasitic diseases that were once considered relatively uncommon in the US. Standard fecal exams on individuals at risk for intestinal parasitosis could help avoid delay in diagnosis and treatment of infections. Clinical laboratory scientists are faced with the continued challenge of maintaining their proficiency in the microscopic identification of parasites since they can potentially alter the clinical outcome of parasite infections, like strongyloidiasis, with good detection skills.

Clin Lab Sci encourages readers to respond with thoughts, questions, or comments regarding this article. Email responses to ic.ink@mchsi.com. In the subject line, please type "CLIN LAB SCI 21(1) CP GREINER". Selected responses will appear in the Dialogue and Discussion section in a future issue. Responses may be edited for length and clarity. We look forward to hearing from you.

REFERENCES

1. Carter E. Epigastric pain, vomiting, and diarrhea in a 47-year-old woman. *Lab Med* 2004;35(3):152-4.
2. Loutfy MR, Wilson M, Keystone JS, and others. Serology and eosinophil count in the diagnosis and management of strongyloidiasis in a non-endemic area. *Am J Trop Med Hyg* 2002;66(6):749-52.
3. Siddiqui AA, Berk SL. Diagnosis of *Strongyloides stercoralis* infection. *Clin Infect Dis* 2001;33(7):1040-7.
4. Nielsen PB, Mojon M. Improved diagnosis of *Strongyloides stercoralis* by seven consecutive stool specimens. *Zentralbl Bakteriol Mikrobiol Hyg (A)* 1987;263(4):616-8.

CLINICAL PRACTICE

- Marquardt WC, Demaree RS, Grieve RB. Parasitology and vector biology. 2nd ed. Burlington, MA: Harcourt/Academic Press;2000:366.
- Siddiqui AA, Guitierrez C, Berk SL. Diagnosis of *Strongyloides stercoralis* by acid-fast staining. J Helminthol 1999;73:187-8.
- Smith B, Verghese A, Guitierrez C, and others. Pulmonary strongyloidiasis. Diagnosis by sputum Gram stain. Am J Med 1985;79(5):663-6.
- John DT, Petri WA. Markell and Voge's medical parasitology. 9th ed. St. Louis, MO: Saunders Elsevier;2006:407-8,429-31.
- Arakaki T, Iwanaga M, Kinjo F, and others. Efficacy of agar-plate culture in detection of *Strongyloides stercoralis* infection. J Parasitol 1990;76(3):425-8.
- Sato Y, Kobayashi J, Toma H, and others. Efficacy of stool examination for detection of *Strongyloides* infection. Am J Trop Med Hyg 1995;53(3):248-50.
- Gam AA, Neva FA, Krotoski WA. Comparative sensitivity and specificity of ELISA and IHA for serodiagnosis of strongyloidiasis with larval antigens. Am J Trop Med Hyg 1987;37(1):157-61.
- Muennig P, Pallin D, Sell RL, and others. The cost effectiveness of strategies for the treatment of intestinal parasites in immigrants. N Eng J Med 1999;340(10):773-9.
- Nair D. Screening for *Strongyloides* infection among the institutionalized mentally disabled. J Am Board Fam Pract 2001;14(1):51-3.
- Braun TI, Fekete T, Lynch A. Strongyloidiasis in an institution for mentally retarded adults. Arch Intern Med 1988;148(33):634-6.
- Schupf N, Ortiz M, Kapell D, and others. Prevalence of intestinal parasite infections among individuals with mental retardation in New York State. Ment Retard 1995;33(2):84-9.
- Heyworth MF. Parasitic diseases in immunocompromised hosts. Cryptosporidiosis, isosporiasis, and strongyloidiasis. Gastroenterol Clin North Am 1996;25(3):691-707.
- Gotuzzo E, Terashima A, Alvarez H, and others. *Strongyloides stercoralis* hyperinfection associated with human T cell lymphotropic virus type-1 infection in Peru. Am J Trop Med Hyg 1999;60(1):146-9.
- Satoh M, Toma H, Sato Y, and others. Reduced efficacy of treatment of strongyloidiasis in HTLV-1 carriers related to enhanced expression of IFN-gamma and TGF-beta 1. Clin Exp Immunol 2002;127(2):354-9.
- Terashima A, Alvarez H, Tello R, and others. Treatment failure in intestinal strongyloidiasis: an indicator of HTLV-1 infection. Int J Infect Dis 2002;6(1):28-30.
- Neva FA, Filho JO, Gam AA, and others. Interferon-gamma and interleukin-4 responses in relation to serum IgE levels in persons infected with human T lymphotropic virus type I and *Strongyloides stercoralis*. J Inf Dis 1998;178(6):1856-9.
- Feitosa G, Bandeira AC, Sampaio DP, and others. High prevalence of giardiasis and strongyloidiasis among HIV-infected patients in Bahia, Brazil. Braz J Infect Dis 2001; 5(6):339-44.
- Sarangarajan R, Ranganathan A, Belmonte AH, and others. *Strongyloides stercoralis* infection in AIDS. AIDS Patient Care STDs 1997;11(6):407-14.
- Cahill KM, Shevchuk M. Fulminant, systemic strongyloidiasis in AIDS. Ann Trop Med Parasitol 1996;90(3):313-8.
- Lessnau KD, Can S, Talavera W. Disseminated *Strongyloides stercoralis* in human immunodeficiency virus-infected patients. Treatment failure and a review of the literature. Chest 1993;104(1):119-22.
- Joshi M, Chowdhary AS, Dalal PJ, and others. Parasitic diarrhoea in patients with AIDS. Natl Med J India 2002;15(2):72-4.

2009 CLEC Abstract Deadline

The deadline for abstracts for poster presentations or technology demonstrations at the 2009 ASCLS Clinical Laboratory Educators Conference (CLEC) is October 1, 2008. Submission instructions and the proposal form may be found at www.ascls.org/conferences. The completed proposal form and abstract must be submitted electronically by the deadline.

The 2009 CLEC will be held February 19-21 in Denver, Colorado. Additional meeting information will be available at the ASCLS Conferences website.