

Warm Autoimmune Hemolytic Anemia Comorbidity and COVID-19 Infection: A Case Report

ISRAEL GOMEZ, SARAH TURKEL, PAYMAN NASR

ABSTRACT

Apart from severe acute respiratory syndrome and cytokine dysregulation, novel coronavirus disease 2019 (COVID-19) infection has also been associated with a broad range of complications including septicemia, thrombosis, thrombocytopenia, Guillain–Barre, antiphospholipid syndrome, and multiple organ failure. Warm autoimmune hemolytic anemia (WAIHA) in its clinical presentation is similar to other forms of hemolytic anemias in which hemoglobin level is the most direct indicator of clinical severity of the hemolytic event. In this report, we describe the case of a 31-year-old male, previously diagnosed with idiopathic WAIHA, who goes on to suffer a severe flare following a COVID-19 infection. Prior to the COVID-19 infection, the patient was in a stable condition and was taking part in a clinical study for the treatment of WAIHA. In the case of this patient, the COVID-19 infection elicited a severe hemolytic episode, which required admission to the hospital and multiple units of blood transfusion. The patient's hematological recovery correlated with improvement from COVID-19 symptoms. The patient was stabilized with glucocorticoids and discharged after 2 weeks of hospitalization. The current case supports the role of COVID-19 infection as a comorbidity factor in WAIHA.

ABBREVIATIONS: ACE-2 - angiotensin-converting enzyme, AIHA - autoimmune hemolytic anemia, CoV - coronavirus, COVID-19 - coronavirus disease 2019, LDH - lactate dehydrogenase, MERS - Middle East respiratory syndrome, RBC - red blood cell, SARS - severe acute respiratory syndrome, SARS-CoV-2 - severe acute respiratory syndrome coronavirus 2, WAIHA - warm autoimmune hemolytic anemia, WBC - white blood cell.

INDEX TERMS: SARS-CoV-2, COVID-19, anemia, hemolytic, autoimmune.

Clin Lab Sci 2024;37(1):12–17

Israel Gomez, California State University, Dominguez Hills

Sarah Turkel, California State University, Dominguez Hills

Payman Nasr, California State University, Dominguez Hills

Address for Correspondence: Payman Nasr, California State University, Dominguez Hills, pnasr@csudh.edu

CASE DESCRIPTION

A 31-year-old Hispanic male sought medical attention after daily headaches, paresthesia, dyspnea, chest pain, and mild cognitive impairment. The patient reported no history of blood transfusion in the past, no history of acute infections or chronic inflammatory conditions. The initial physical exam showed a general pallor paleness of the skin, blood pressure 140/100 mmHg, with fast but strong heartbeats (95 beats/min), and palpable spleen on deep inspiration. The transverse and longitudinal ultrasound showed mild hepatosplenomegaly with hepatic steatosis, and the spleen was palpable on the left upper abdomen on deep inspiration. The first laboratory results were remarkable for erythrocytopenia: low hemoglobin and hematocrit and an increase in reticulocyte percentage, total bilirubin, and sedimentation rate. Lactate dehydrogenase (LDH) was slightly elevated (238 U/L; reference 135–225 U/L). Haptoglobin concentration was below the instrument detection limit (<15 mg/dL). The liver profile was unremarkable, and the acute hepatitis panel was non-reactive. Iron studies included the percent transferrin saturation rate and the total iron-binding capacity within the reference intervals, whereas ferritin was elevated (500 ug/L; reference 26–336 ug/L). Direct antiglobulin test was positive for anti-IgG and anti-C3. Clinical assessments excluded mineral and vitamin deficiencies, lymphoproliferative disorders, nonlymphoid neoplasms, rheumatoid arthritis, systemic lupus erythematosus, and immunodeficiency disorders and, ultimately, yielded the diagnosis of idiopathic IgG plus complement warm autoimmune hemolytic anemia (WAIHA). Refer to Figure 1 to view the progression of the disease and the associated treatment interventions.

Attaining and maintaining remission proved challenging. Following diagnosis, prednisone (110 mg/day) was administered for 2 months with taper. Laboratory parameters normalized in 1 month, but after a 3-month remission, symptoms recurred characterized by a rapid drop in hemoglobin. As an alternative therapy, the patient received pulse dexamethasone 40 mg daily for 4 days, with alleviation of symptoms. A 3-month remission was followed by another relapse. A new treatment approach with dexamethasone and rituximab, a monoclonal antibody targeting CD20-positive B lymphocytes (2 doses of 1000 mg of rituximab with 40 mg dexamethasone for 4 days), was administered, improving the physical symptoms and normalizing the laboratory parameters within

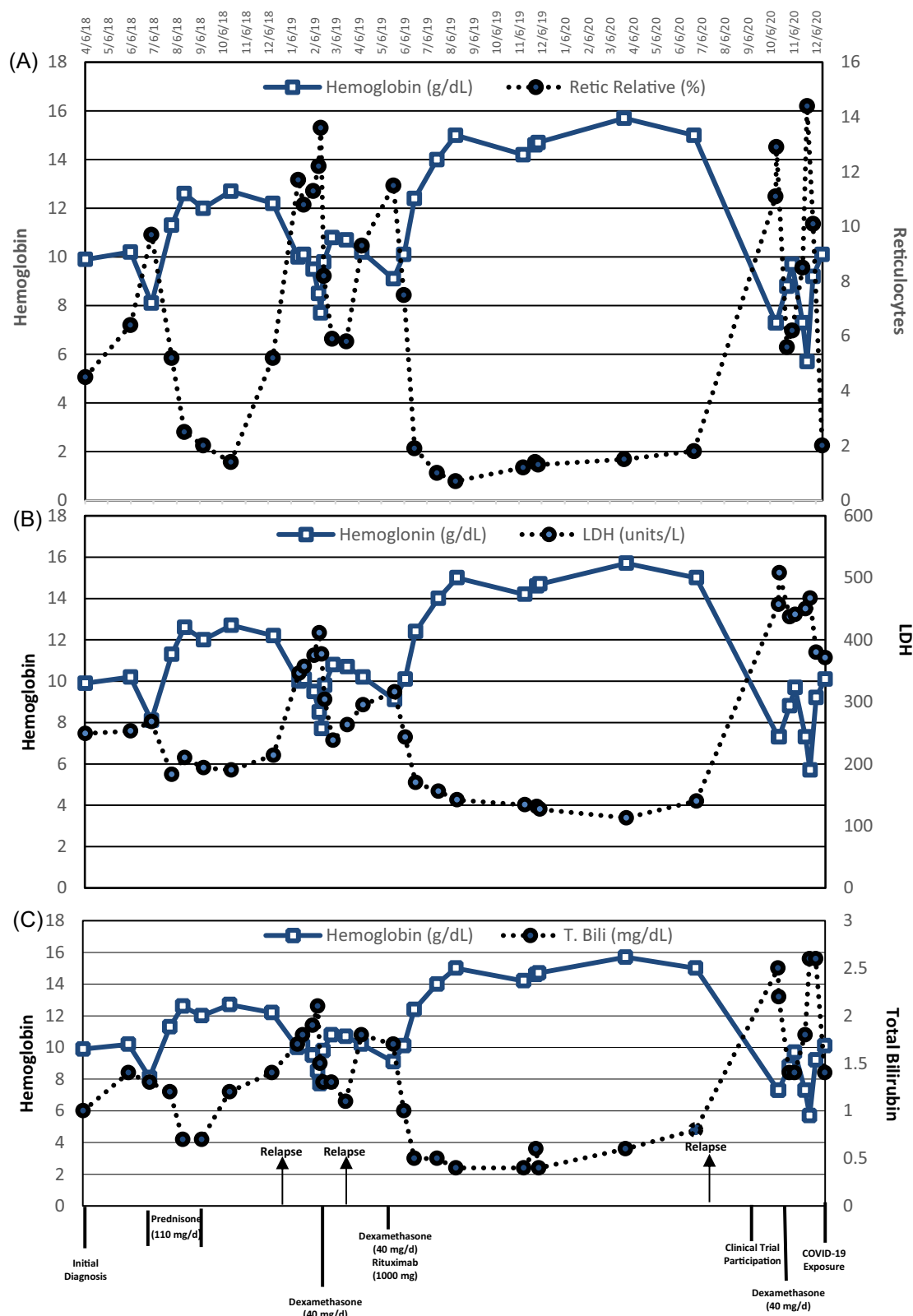


Figure 1. The chronological comparison of the laboratory results for the relative reticulocyte percentage, lactate dehydrogenase (LDH), and total bilirubin (T. Bili), with respect to the hemoglobin values since the onset of the first hemolytic episode. (A) Hemoglobin versus relative reticulocyte percentage, (B) hemoglobin versus LDH, (C) hemoglobin versus total bilirubin. The arrows indicate relapses, whereas the straight vertical lines show each treatment regimen.

2 weeks. The patient remained in remission for 16 months before the recurrence of the hemolysis and anemia symptoms, at which time he joined a multicenter, randomized, double-blind, placebo-controlled study of fostamatinib disodium hexahydrate for the treatment of WAIHA. Following the treatment with 40 mg dexamethasone for 4 days, hemoglobin value was stabilized at 10 mg/dL with the resumption of daily activities. Figure 1A–C shows patient's percent reticulocytes, LDH, and total bilirubin with respect to the hemoglobin concentration from the initial diagnosis to the coronavirus disease 2019 (COVID-19) exposure.

On December 7, 2020, the subject's father, who lived in the same household, was notified of COVID-19 exposure at his workplace. Same-day COVID-19 testing was negative for every member of the household. The next testing on December 10, however, showed a positive result for the father. Every member of the household, including the case subject, tested positive 1 day later on December 11. On December 14, 3 days following the positive COVID-19 result, although the case subject was physically asymptomatic for COVID-19, the laboratory results showed a general pancytopenia (white blood cell [WBC] count $1.52 \times 10^9/L$, red blood cell [RBC] count $3.15 \times 10^{12}/L$, platelets $121 \times 10^9/L$) and early signs of hemolysis (hemoglobin 10.1 mg/dL, LDH 371 U/L, haptoglobin <15 mg/dL, total bilirubin 2.0 mg/dL). On December 19, the patient reported the symptoms of a hemolytic episode (eg, severe fatigue, fever, dark urine color), which led to his hospitalization. The hemoglobin value on the date of hospital admission was 6.8 mg/dL, whereas unlike the previous hemolytic episodes, the D-dimer (>20 ug/ml; reference <0.6 ug/ml) and the fibrinogen (505 mg/dL; reference 235–490 mg/dL) were elevated. The patient was initiated on a regimen of steroids (dexamethasone 40 mg/daily for 4 days) and prophylactic anticoagulant therapy (enoxaparin sodium 40 mg subcutaneous) and monitored closely for deep vein thrombosis and pulmonary embolism. The continuous drop in hemoglobin prompted blood transfusion. On December 20, the first unit of blood was transfused, which resulted in a transfusion reaction and a severe hemolytic episode with a subsequent hemoglobin of 3.9 mg/dL. The patient received 7 additional units of irradiated and washed RBCs at a slow rate of infusion over the next 9 days. Table 1 shows the values for hemoglobin, total bilirubin, fibrinogen, and D-dimer and the treatment notes from the hospital admission to discharge.

CASE RESOLUTION

The patient's hematological recovery trended with improvement from COVID-19 symptoms. As the COVID-19 symptoms were resolved, the reticulocyte values recovered (19.2% on 12/30/2020). The patient was kept on a treatment with 110 mg daily prednisone until the hemoglobin values increased to 8.1 mg/dL, at which time the

patient was discharged taking 50 mg of prednisone a day, with taper.

DISCUSSION

Since the World Health Organization declared COVID-19, which is principally a respiratory infection, a pandemic on March 11, 2020, clinicians have been reporting extrapulmonary complications.^{1–4} Severe acute respiratory syndrome coronavirus-2 (SARS-CoV-2) has been associated with cardiac, neurologic, dermatological, renal, and gastroenterological manifestations and septicemia, Guillain-Barre, antiphospholipid syndrome, and multiple organ failure.^{5–8} Hematologic abnormalities have also been reported following COVID-19 infection, with alterations seen in platelets, RBCs, hemoglobin, lymphocyte, granulocyte, monocyte, macrophage, and coagulation responses.^{9,10} SARS-CoV-2 has also been implicated in immune dysregulation and the development of autoimmune diseases.^{10–13} The relationship between viral infections and the potential development of autoimmune diseases is widely acknowledged. A number of hypotheses have been proposed to explain how and why this occurs, with molecular mimicry or crossreactivity cited in many cases.^{2,14,15} Along with severe acute respiratory syndrome (SARS)-coronavirus (CoV) and Middle East respiratory syndrome (MERS)-CoV, SARS-CoV-2 is classified as a β -CoV and is commonly associated with severe respiratory syndrome.^{16–18} It has been reported that SARS-CoV-2 utilizes angiotensin-converting enzyme (ACE-2) receptor to penetrate and infect the cells similarly to mechanisms seen in other SARS-CoV infections.^{19,20} CoVs have 4 structural proteins: spike (S), membrane (M), envelope (E), and nucleocapsid (N).²¹ The proposed model for viral fusion requires a 2-step protease cleavage to activate the spike protein, which has been identified to be used by SARS-CoV and MERS-CoV to enter the cells after binding ACE-2. However, SARS-CoV-2 also utilizes protease furin, which other CoVs have not shown to use and may account for increased SARS-CoV-2 pathogenicity.³ It is speculated that the presence of redundant furin cut sites in the spike protein is responsible for SARS-CoV-2's higher membrane fusion efficiency and enhanced pathogenicity compared with other CoVs.²² ACE-2 and furin are coexpressed membrane endopeptidase of the ACE-2 receptor, and furin has the potential to cleave the viral envelop glycoprotein, thereby enhancing the viral fusion with host cell membranes.^{23–25}

Although hematologic autoimmune cases, including autoimmune hemolytic anemia (AIHA), linked to COVID-19 infection, are slowly being reported,^{26,27} the impact of COVID-19 on preexisting AIHA has only been documented in isolated cases. The current literature has primarily focused on patients who have developed AIHA during or post-COVID-19 infection. Lazarian et al described 7 patients who developed AIHA after testing positive for COVID-19.²⁷ Lopez et al reported a case of

Table 1. Hemoglobin, total bilirubin, and treatment notes

Date	Hgb (mg/dL)	T. Bili (mg/dL)	Fibrinogen (mg/dL)	D-Dimer (ug/ml)	Treatment Notes
12/11/20	nt	nt	nt	nt	COVID-19 test positive
12/14/20	10.1	2.0	nt	nt	Pancytopenia; elevated hemolysis indices
12/19/20	6.8	3.1	505	0.96	Hospital admission
12/20/20	5.6	5.0	454	>20	1 unit (Rh, Kell matched) caused exacerbation of hemolysis triggered by transfusion reaction; dexamethasone; enoxaparin
12/21/20	3.9	4.7	433	>20	1 unit phenotypically matched, irradiated, washed, and infused over 8 hours; dexamethasone; enoxaparin
12/22/20	5.2	2.8	nt	4.72	No transfusion; dexamethasone; IVIG; rivaroxaban
12/23/20	4.9	2.5	419	2.02	No transfusion; dexamethasone; EPO; IVIG; rivaroxaban
12/24/20	4.5	4.4	nt	1.68	1 unit phenotypically matched, irradiated, and washed infused over 8 hours; EPO; IVIG; rivaroxaban
12/25/20	4.4	5.3	504	1.88	1 unit phenotypically matched, irradiated, and washed infused over 8 hours; prednisone; EPO; rivaroxaban
12/26/20	4.0	4.5	515	1.59	1 unit phenotypically matched, irradiated, and washed infused over 8 hours; prednisone; EPO; rivaroxaban
12/27/20	4.0	4.5	536	1.27	1.5 units phenotypically matched, irradiated, and washed infused over 8 hours; prednisone; EPO; rivaroxaban; discontinued participation in the clinical study
12/28/20	6.1	4.4	518	1.04	2.5 units phenotypically matched, irradiated, and washed infused at a slow rate; prednisone; EPO; rivaroxaban
12/29/20	7.3	2.5	nt	nt	1 unit phenotypically matched, irradiated, and washed infused over 8 hours; prednisone; EPO; rivaroxaban
12/30/20	7.3	2.5	nt	2.21	Prednisone; EPO; rivaroxaban
12/31/20	7.4	2.4	nt	nt	Prednisone; EPO; COVID-19 PCR test negative; rivaroxaban
1/1/21	8.1	2.4	nt	1.49	Discharged; maintained on 50 mg daily prednisone

Patient's hemoglobin, T. Bili, fibrinogen, D-dimer, and daily treatment notes following COVID-19 infection and hospitalization are shown in a chronological order. Dexamethasone, 40 mg; enoxaparin, 40 mg; EPO, epoetin alfa 40 000 units/mL; Hgb, hemoglobin; IVIG, immune globulin 500 mg/kg infusion; nt, not tested; PCR, polymerase chain reaction; prednisone, 110 mg; rivaroxaban, 10 mg; T. Bili, total bilirubin.

simultaneous presentation of COVID-19 and WAIHA.²⁶ Hindilerden et al presented a case of a patient with moderate COVID-19 pneumonia who went on to develop AIHA,²⁸ whereas Capes et al described a patient in the intensive care unit suffering from COVID-19 infection who, at around 2 weeks after admission, began showing

signs and symptoms of AIHA.²⁹ Most recently, Finkenthal et al published a case of a patient with a history of well-controlled AIHA secondary to systemic lupus erythematosus whose AIHA was exacerbated by COVID-19 infection.³⁰ WAIHA is the most common form of AIHA and is characterized by binding of panreactive polyclonal IgG to Rh

proteins or glycoporphins on the RBC surface optimally at 37 °C, targeting the cells for premature removal by macrophages in the spleen and other extravascular sites.³¹ The clinical presentation of WAIHA ranges from general symptoms of anemia (fatigue, dyspnea, tachycardia) in mild cases, to fever, jaundice, hepatosplenomegaly, and renal failure in the more severe cases.³² Corticosteroid therapy is the standard initial treatment for moderate to severe cases of WAIHA, whereas in recent years, a combination therapy with rituximab, a chimeric, mouse/human, monoclonal antibody targeting CD20, has shown promising results.³³ In the current case, following the rituximab with dexamethasone pulse therapy, the laboratory parameters normalized within 2 weeks, and the hemoglobin level achieved the highest level since the first onset of symptoms, a goal that was not reached with glucocorticoid monotherapy. The patient remained in remission for 16 months before relapse, at which time the patient joined a double-blind clinical trial for fostamatinib disodium hexahydrate, a tyrosine kinase inhibitor. The subject had to withdraw from the clinical study during a severe hemolytic crisis following COVID-19 infection. Three days after a positive COVID-19 test result, although the subject was asymptomatic for COVID-19, the laboratory results showed elevated hemolysis marker and pancytopenia. The subject was hospitalized 8 days after the initial positive COVID-19 test results with mild respiratory symptoms and a severe hemolytic episode that was exacerbated by the blood transfusion reaction, which highlights the therapeutic application of irradiated blood at a low infusion rate in patients with autoimmune disorders (see Table 1).

Following the hospital admission, the initial laboratory results showed an increase in D-dimer and a mild elevation in fibrinogen, indicating a hypercoagulability state. Previous reports have shown that COVID-19 infection may result in elevated coagulation levels and poor prognosis.³⁴⁻³⁶ However, in the current case, considering the application of prophylactic anticoagulant therapy, the patient's results did not meet the criteria set by the International Society on Thrombosis and Haemostasis for Disseminated Intravascular Coagulation Score (<5).³⁷⁻³⁹

Although it is difficult to determine the exact dynamics of the hemolytic crisis, immunosuppressive treatments, and COVID-19 infection, the current case suggests that COVID-19 infection exacerbated the hemolytic episode by inducing pancytopenia as detected by decreased reticulocytes, WBCs, and platelets before the onset of the COVID-19 symptoms. The case outcomes also suggest that the standard treatment of AIHA with corticosteroids is unaffected by the COVID-19 pandemic, but the addition of COVID-19 may worsen the hemolytic episode and require hospitalization and multiple-unit blood transfusion. The current case describes a patient with WAIHA who goes on to experience a severe flare and hemolytic episode after COVID-19 infection. This report aims to contribute to the small but growing body of evidence that examines the risks associated with

COVID-19 infection in patients who have previously been diagnosed with WAIHA.

ACKNOWLEDGEMENTS

The authors wish to thank Professor Cheryl Jackson-Harris for her invaluable input in the case assessment.

FUNDING

The American Society of Clinical Pathologists Laboratory Science Program Director Educational Grant, 2021.

REFERENCES

- Dotan A, Muller S, Kanduc D, David P, Halpert G, Shoenfeld Y. The SARS-CoV-2 as an instrumental trigger of autoimmunity. *Autoimmun Rev.* 2021;20(4):102792. doi: [10.1016/j.autrev.2021.102792](https://doi.org/10.1016/j.autrev.2021.102792)
- Yazdanpanah N, Rezaei N. Autoimmune complications of COVID-19. *J Med Virol.* 2022;94(1):54–62. doi: [10.1002/jmv.27292](https://doi.org/10.1002/jmv.27292)
- Yuki K, Fujiogi M, Koutsogiannaki S. COVID-19 pathophysiology: a review. *Clin Immunol.* 2020;215:108427. doi: [10.1016/j.clim.2020.108427](https://doi.org/10.1016/j.clim.2020.108427)
- CDC Museum. COVID-19 timeline. *David J. Sencer CDC Museum.* <https://www.cdc.gov/museum/timeline/covid19.html>. Accessed July 22, 2022.
- Khan F, Sharma P, Pandey S, et al. COVID-19-associated Guillain-Barre syndrome: postinfectious alone or neuroinvasive too? *J Med Virol.* 2021;93(10):6045–6049. doi: [10.1002/jmv.27159](https://doi.org/10.1002/jmv.27159)
- Gupta A, Madhavan MV, Sehgal K, et al. Extrapulmonary manifestations of COVID-19. *Nat Med.* 2020;26(7):1017–1032. doi: [10.1038/s41591-020-0968-3](https://doi.org/10.1038/s41591-020-0968-3)
- Elrobaa IH, New KJ. COVID-19: pulmonary and extra pulmonary manifestations. *Front Public Health.* 2021;9:711616. doi: [10.3389/fpubh.2021.711616](https://doi.org/10.3389/fpubh.2021.711616)
- Lopes-Pacheco M, Silva PL, Cruz FF, et al. Pathogenesis of multiple organ injury in COVID-19 and potential therapeutic strategies. *Front Physiol.* 2021;12:593223. doi: [10.3389/fphys.2021.593223](https://doi.org/10.3389/fphys.2021.593223)
- Rahman A, Niloofa R, Jayarajah U, De Mel S, Abeysuriya V, Seneviratne SL. Hematological Abnormalities in COVID-19: A Narrative Review. *Am J Trop Med Hyg.* 2021;104(4):1188–1201. doi: [10.4269/ajtmh.20-1536](https://doi.org/10.4269/ajtmh.20-1536)
- Erdinc B, Sahni S, Gotlieb V. Hematological manifestations and complications of COVID-19. *Adv Clin Exp Med.* 2021;30(1):101–107. doi: [10.17219/acem/130604](https://doi.org/10.17219/acem/130604)
- Giacaman A, Henriquez W, Tolosa G, et al. Hematological abnormalities in immunosuppressed patients with COVID-19: evidence from a single center. A cross sectional study. *Int Immunopharmacol.* 2022;109:108862–108862. doi: [10.1016/J.intimp.2022.108862](https://doi.org/10.1016/J.intimp.2022.108862)
- Şener G, Bayrak T, Coşkun C, Bayrak A. Neutrophil lymphocyte ratio, monocyte lymphocyte ratio, platelet lymphocyte ratio in Covid-19 patients. *Clin Lab.* 2022;68(3):565–573. doi: [10.7754/Clin.Lab.2021.210639](https://doi.org/10.7754/Clin.Lab.2021.210639)
- Su M, Ouyang X, Song Y. Neutrophil to lymphocyte ratio, platelet to lymphocyte ratio, and monocyte to lymphocyte ratio in depression: a meta-analysis. *J Affect Disord.* 2022;308:375–383. doi: [10.1016/j.jad.2022.04.038](https://doi.org/10.1016/j.jad.2022.04.038)

14. Cappello F. COVID-19 and molecular mimicry: the Columbus' egg? *J Clin Neurosci*. 2020;77:246. doi: [10.1016/j.jocn.2020.05.015](https://doi.org/10.1016/j.jocn.2020.05.015)
15. Cappello F. Is COVID-19 a proteiform disease inducing also molecular mimicry phenomena? *Cell Stress Chaperones*. 2020;25(3):381–382. doi: [10.1007/s12192-020-01112-1](https://doi.org/10.1007/s12192-020-01112-1)
16. Andersen KG, Rambaut A, Lipkin WI, Holmes EC, Garry RF. The proximal origin of SARS-CoV-2. *Nat Med*. 2020;26(4):450–452. doi: [10.1038/s41591-020-0820-9](https://doi.org/10.1038/s41591-020-0820-9)
17. Zaki AM, van Boheemen S, Bestebroer TM, Osterhaus ADME, Fouchier RAM. Isolation of a novel coronavirus from a man with pneumonia in Saudi Arabia. *N Engl J Med*. 2012;367(19):1814–1820. doi: [10.1056/NEJMoa1211721](https://doi.org/10.1056/NEJMoa1211721)
18. Sallard E, Halloy J, Casane D, Decroly E, van Helden J. Tracing the origins of SARS-CoV-2 in coronavirus phylogenies: a review. *Environ Chem Lett*. 2021;19(2):769–785. doi: [10.1007/s10311-020-01151-1](https://doi.org/10.1007/s10311-020-01151-1)
19. Kuba K, Imai Y, Rao S, et al. A crucial role of angiotensin converting enzyme 2 (ACE2) in SARS coronavirus-induced lung injury. *Nat Med*. 2005;11(8):875–879. doi: [10.1038/nm1267](https://doi.org/10.1038/nm1267)
20. Murray E, Tomaszewski M, Guzik TJ. Binding of SARS-CoV-2 and angiotensin-converting enzyme 2: clinical implications. *Cardiovasc Res*. 2020;116(7):e87–e89. doi: [10.1093/cvr/cvaa096](https://doi.org/10.1093/cvr/cvaa096)
21. Yadav R, Chaudhary JK, Jain N, et al. Role of structural and non-structural proteins and therapeutic targets of SARS-CoV-2 for COVID-19. *Cells*. 2021;10(4):821. doi: [10.3390/cells10040821](https://doi.org/10.3390/cells10040821)
22. Wu C, Zheng M, Yang Y, et al. Furin: a potential therapeutic target for COVID-19. *iScience*. 2020;23(10):101642. doi: [10.1016/j.isci.2020.101642](https://doi.org/10.1016/j.isci.2020.101642)
23. Ye X, de Rezende WC, Iwuchukwu OP, et al. Antibody response to the furin cleavable twenty-seven amino acid peptide (p27) of the fusion protein in respiratory syncytial virus (RSV) infected adult hematopoietic cell transplant (HCT) recipients. *Vaccines (Basel)*. 2020;8(2):192. doi: [10.3390/vaccines8020192](https://doi.org/10.3390/vaccines8020192)
24. Salamanna F, Maglio M, Landini MP, Fini M. Body localization of ACE-2: on the trail of the keyhole of SARS-CoV-2. *Front Med (Lausanne)*. 2020;7:594495. doi: [10.3389/fmed.2020.594495](https://doi.org/10.3389/fmed.2020.594495)
25. Izaguirre G. The proteolytic regulation of virus cell entry by furin and other proprotein convertases. *Viruses*. 2019;11(9):837. doi: [10.3390/v11090837](https://doi.org/10.3390/v11090837)
26. Lopez C, Kim J, Pandey A, Huang T, DeLoughery TG. Simultaneous onset of COVID-19 and autoimmune haemolytic anaemia. *Br J Haematol*. 2020;190(1):31–32. doi: [10.1111/bjh.16786](https://doi.org/10.1111/bjh.16786)
27. Lazarian G, Quinquenel A, Bellal M, et al. Autoimmune haemolytic anaemia associated with COVID-19 infection. *Br J Haematol*. 2020;190(1):29–31. doi: [10.1111/bjh.16794](https://doi.org/10.1111/bjh.16794)
28. Hindilerden F, Yonal-Hindilerden I, Akar E, Yesilbag Z, Kart-Yasar K. Severe autoimmune hemolytic anemia in COVID-19 infection, safely treated with steroids. *Mediterr J Hematol Infect Dis*. 2020;12(1):e2020053. doi: [10.4084/mjhid.2020.053](https://doi.org/10.4084/mjhid.2020.053)
29. Capes A, Bailly S, Hantson P, Gerard L, Laterre PF. COVID-19 infection associated with autoimmune hemolytic anemia. *Ann Hematol*. 2020;99(7):1679–1680. doi: [10.1007/s00277-020-04137-9](https://doi.org/10.1007/s00277-020-04137-9)
30. Finkenthal TA, Aldaher Z, Ahmed S, DiValentin L. Autoimmune hemolytic anemia exacerbation associated with COVID-19 infection and markedly elevated inflammatory markers. *Cureus*. 2021;13(12):e20416. doi: [10.7759/cureus.20416](https://doi.org/10.7759/cureus.20416)
31. Kalfa TA. Warm antibody autoimmune hemolytic anemia. *Hematology (Am Soc Hematol Educ Program)*. 2016;2016(1):690–697. doi: [10.1182/asheducation-2016.1.690](https://doi.org/10.1182/asheducation-2016.1.690)
32. Barcellini W, Fattizzo B. Clinical applications of hemolytic markers in the differential diagnosis and management of hemolytic anemia. *Dis Markers*. 2015;2015:635670. doi: [10.1155/2015/635670](https://doi.org/10.1155/2015/635670)
33. Reynaud Q, Durieu I, Dutertre M, et al. Efficacy and safety of rituximab in auto-immune hemolytic anemia: a meta-analysis of 21 studies. *Autoimmun Rev*. 2015;14(4):304–313. doi: [10.1016/j.autrev.2014.11.014](https://doi.org/10.1016/j.autrev.2014.11.014)
34. Arachchillage DRJ, Laffan M. Abnormal coagulation parameters are associated with poor prognosis in patients with novel coronavirus pneumonia. *J Thromb Haemost*. 2020;18(5):1233–1234. doi: [10.1111/jth.14820](https://doi.org/10.1111/jth.14820)
35. Lillcrap D. Disseminated intravascular coagulation in patients with 2019-nCoV pneumonia. *J Thromb Haemost*. 2020;18(4):786–787. doi: [10.1111/jth.14781](https://doi.org/10.1111/jth.14781)
36. Tang N, Li D, Wang X, Sun Z. Abnormal coagulation parameters are associated with poor prognosis in patients with novel coronavirus pneumonia. *J Thromb Haemost*. 2020;18(4):844–847. doi: [10.1111/jth.14768](https://doi.org/10.1111/jth.14768)
37. Taylor FB Jr, Toh CH, Hoots WK, Wada H, Levi M; SSC on Disseminated Intravascular Coagulation of the ISTH. Towards definition, clinical and laboratory criteria, and a scoring system for disseminated intravascular coagulation. *Thromb Haemost*. 2001;86(5):1327–1330.
38. Toh CH, Hoots WK. The scoring system of the Scientific and Standardisation Committee on Disseminated Intravascular Coagulation of the International Society on Thrombosis and Haemostasis: a 5-year overview. *J Thromb Haemost*. 2007;5(3):604–606. doi: [10.1111/j.1538-7836.2007.02313.x](https://doi.org/10.1111/j.1538-7836.2007.02313.x)
39. Larsen JB, Aggerbeck MA, Granfeldt A, Schmidt M, Hvas AM, Adelborg K. Disseminated intravascular coagulation diagnosis: positive predictive value of the ISTH score in a Danish population. *Res Pract Thromb Haemost*. 2021;5(8):e12636. doi: [10.1002/rth2.12636](https://doi.org/10.1002/rth2.12636)